

# Cerebrospinal Fluid Protein Changes in Multiple Sclerosis After Dental Amalgam Removal

by Hal A. Huggins, D.D.S., M.S. and Thomas E. Levy, M.D., J.D., F.A.C.C.

## Abstract:

A relationship between multiple sclerosis (MS) and dental silver-mercury fillings has been suggested by some investigators, but never proven. This study documents objective biochemical changes following the removal of these fillings along with other dental materials, utilizing a new health care model of multidisciplinary planning and treatment. The dramatic changes in photolabeling of cerebrospinal fluid (CSF) proteins following these dental interventions suggest CSF photolabeling may serve as an objective biomarker for monitoring MS. The clear-cut character of these changes should also encourage more research to better define this possible association between dental mercury and MS.

(*Altern Med Rev* 1998;3(4):295-300)

## Introduction

Multiple sclerosis (MS) is a multifocal disease of the white matter of the central nervous system (CNS) characterized by inflammation, demyelination, and gliosis. Clinical symptoms reflect the variable locations of the lesions in different patients. Certain protein patterns in the cerebrospinal fluid (CSF) of MS patients are typically present, notably remaining unchanged in the absence of dramatic clinical exacerbations and remissions.

Some reports in the literature suggest a correlation between MS and exposure to mercury from dental amalgam fillings.<sup>1-8</sup> Amalgam fillings generally contain approximately 50 percent mercury in a complex mixture of copper, tin, silver, and zinc. It has been well documented that this mixture continually emits mercury vapor, which is dramatically increased by chewing, eating, brushing, and drinking hot liquids.<sup>9</sup>

Although the primary thrust of this study explores the relationship between mercury and the neurological system, some early controversial research implicated root canal filled teeth in neurological diseases, although not MS specifically.<sup>10,11</sup> Accordingly, the removal of root canal filled teeth was included in the patient treatment protocol.

This article addresses the possibility that dental materials, specifically those including mercury, may be an important factor in producing the abnormal protein profile seen in the CSF of MS patients. Changes in the patterns and amounts of CSF proteins never before reported

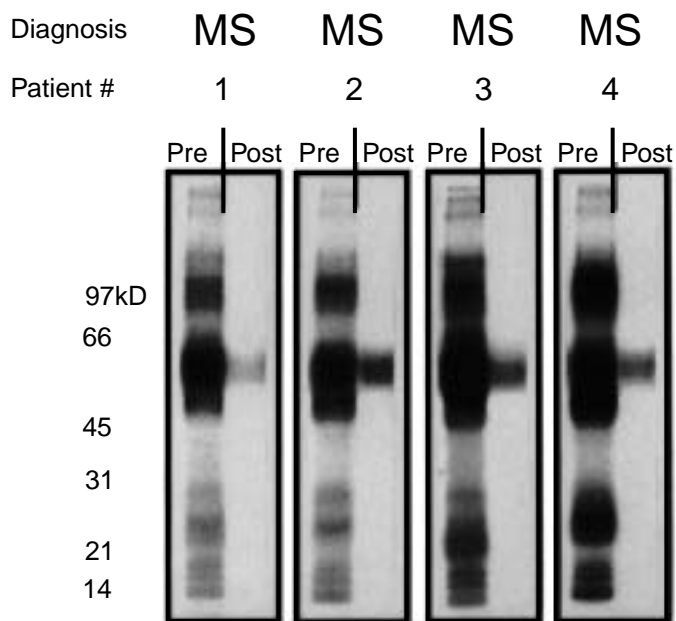
---

Hal A. Huggins, DDS, MS (immunology and toxicology) – has spent the past 35 years researching the toxicity of dental amalgams and is currently consulting at The Center for Progressive Medicine in Puerto Vallarta, Mexico.

Correspondence address: 5080 List Drive, Colorado Springs, CO 80919.

Thomas E. Levy, MD, JD, Board certified in Cardiology. President, Peak Energy Performance, Inc.

**Figure 1.** Cerebrospinal proteins before and after dental revision.



Results of [<sup>32</sup>P]8N3ATP photolabeling of eight cerebrospinal fluid samples pre- and 24-48 hour post-total dental amalgam removal in four patients with previously diagnosed multiple sclerosis. There is a similarity between the albumin bands, but a dramatic shift in all other proteins.

have been found in CSF specimens of MS patients after undergoing a multidisciplinary treatment protocol. This protocol included replacement of all amalgams with composite fillings and removal of root canal filled teeth and other infected teeth. Additionally, the treatment included medical, dental, psychological, nursing, nutritional, and neuromuscular therapies. Intravenous vitamin C, along with several detoxification procedures, was also utilized.

### Materials and Methods

Patient selection was based on the patient having been diagnosed with MS by magnetic resonance imaging prior to entering our center, as well as being available at a period in time when the spinal taps, dental treatment, and laboratory services were concurrently available.

### Laboratory Procedures

Eight 1.5 ml CSF samples (four pre-treatment and four post-treatment on the same four patients) were obtained by lumbar puncture and frozen at -20°C within one hour. The specimens were stored on dry ice and transferred to the Haley Laboratory at the University of Kentucky Medical Center. After thawing on ice, the specimens were apportioned into individual 20 microliter aliquots in Eppendorf tubes. These samples were stored at -70°C until the time of the testing. All eight samples were then tested on a *single gel* at the *same time* with all external conditions being identical.

Twenty microliter aliquots of each of the eight lumbar CSF samples were removed from -70°C storage and thawed on ice. They were then preincubated for 30 minutes at 4°C in a reaction mixture of 20 mM sodium phosphate buffer (pH 7.0) containing 0.5 mM CaCl<sub>2</sub> and 0.2 mM MgCl<sub>2</sub>,

making a reaction volume of 90 microliters. Next, a 10 microliter aliquot of [<sup>32</sup>P]8N3ATP (8-azidoadenosine 5'-triphosphate) made in the same buffer was added to give a final test concentration of 25 micromolar [μM] (specific activity of 10-20 mCi/mole) in a final test volume of 100 microliters.

The samples were then incubated for 30 seconds with the photoprobe at 4°C, followed immediately by 60 seconds of photolysis at 254 nm with a hand-held UV lamp (intensity = 6600 W/cm<sup>2</sup>). Immediately after photolabeling, a 300 microliter aliquot of ice-cold 7 percent perchloric acid was added to each test to quench the reaction and precipitate the proteins. Samples were then incubated on ice for 10 minutes, and the proteins were precipitated by spinning in a Fisher microcentrifuge at 13,000 x g for four minutes at 4°C.

Supernatants were then aspirated and the protein pellets dissolved in 45 microliters of protein solubilizing mixture containing 5 M urea, 0.125 M Tris-HCl, pH 6.8, 0.2 percent SDS, 5 percent 2-mercaptoethanol, and 0.05 percent bromphenol blue as a tracking dye.

The solubilized proteins were then subjected to electrophoresis on a 6-10 percent gradient SDS-PA gel with a 4 percent stacking gel, according to the method of Laemmli.<sup>12,13</sup> A constant current of 35 mA was applied until the front dye eluted from the bottom of the gel. Afterwards, the SDS-PA gel was stained with 3 percent Coomassie brilliant blue BBR-250 for one hour and destained overnight for 12 hours. The stained gel was then dried on a vacuum slab dryer with heat, and the dried gel was exposed to X-ray film.

### Dental Clinical Procedures

Guidelines in the selection of treatment modalities were based upon dental procedures which have been found to produce consistent improvements in numerous blood chemistries, antibody titers, CBC, T-subset analysis, lymphocyte viability testing, urine and blood mercury levels, cooximetry, blood pressure, pulse, body temperature, and symptom improvement as seen over a period of 23 years (authors' unpublished observations).

If one were to duplicate this procedure in an attempt to obtain similar results, the entire protocol would have to be used, for we have observed clinically that if one or more of these steps is eliminated, the results can be compromised. We realize the reader may find many of these procedures unfamiliar, but we also must address the fact that anecdotal reports to us of patients treated by removal of mercury fillings *alone* have produced far more failures than favorable comments.

Appointments in a dental office are of necessity accompanied by exposures to mercury vapor in the air from the removal of amal-

gam fillings with high speed drills.<sup>14,15</sup> Each exposure initiates a circaseptan immune cycle similar to that seen in administering chemotherapy.<sup>16</sup> For this reason, appointments were scheduled to avoid mercury vapor exposures on days 7, 14, and 21 after the initial exposure, as well as subsequent exposures.

To further protect the patient from mercury exposure, each patient was fitted with a rubber dam, which somewhat isolates the teeth during amalgam removal procedures, minimizing any inadvertent swallowing of particulate amalgam. The dental operatories were equipped with negative ion generators, charcoal air filters, and high suction evacuation capability from the oral cavity.

Serum biocompatibility testing was performed on all patients to choose optimal replacement filling materials. Each patient's blood serum was exposed to the components of the composite dental materials available. Selection of a material was based on finding one that would not form an antigen-antibody complex when challenged. The presence of a complexing reaction was based on changes in optical density of the serum as measured by a Dynatec MR 5000 Optical Density Scanner.

Intravenous vitamin C was administered at a rate of approximately 200 milligrams per minute before, during, and after the dental procedures, usually taking about 3.5 hours. The total dose ranged from 35-40 grams per dental visit.

Individual blood chemistries were the basis of nutritional selections for the amount of carbohydrate, protein, and fat for each patient's diet. Patients were advised to limit sugar, alcohol, and caffeine in their diets.

### Results

CSF 1-D SDS-PA "before" gels on all four patients showed heavy photolabeling of multiple proteins. The "after" gels, run on CSF specimens obtained 24-48 hours after completion of the dental procedures, showed a near

absence of labeling, except in the 66 kDa area of albumin. (see Figure 1) To help minimize the possible influence of circadian variation in the presence of certain proteins in the CSF, all “before” spinal taps were obtained within two hours of the time of day of the “after” spinal taps. Some albumin labeling did appear lighter in the “after” tap fluid.

Of special interest was the similarity of results obtained, considering the variable clinical status of the patients. Two of the patients, No. 1 (age 53 – the only male in the group) and No. 3 (age 28), were totally confined to wheelchairs. Number 2 (age 52) used crutches and a wheelchair, and No. 4 (age 49) walked unassisted but fell frequently. Despite this clinical variability there was remarkable reproducibility in the “after” results of CSF as shown by gel electrophoresis.

The reductions of ceruloplasmin, transferrin, IgG heavy and light chains, Apo E, transthyretin, and other proteins raise many questions about the relationship between mercury and MS. Is the reduction of protein photolabeling the result of a reduction in the amount of protein or is it a change in the photolabeling characteristics? Either possibility raises additional questions in need of further research.

## Discussion

There is now general agreement that mercury is released from dental amalgam in the form of  $Hg^0$ .<sup>17</sup> Mercury vapor ( $Hg^0$ ) is more likely than  $Hg^{2+}$  to concentrate in the CNS after it has passed the blood-brain barrier, helping explain much of its neurotoxicity. Inhaled mercury vapor (as from fillings) is highly lipophilic, or fat-soluble, allowing its ready passage into the blood through the alveolar membranes of the lungs. After this absorption, mercury vapor persists in the circulation long enough to permit much of it to diffuse across the blood-brain barrier. Once in the brain, it is

oxidized by the intracellular hydrogen peroxide-catalase system to its divalent cation,  $Hg^{2+}$ . Since the  $Hg^{2+}$  form cannot diffuse out of the different nerve cells after this transformation, mercury gradually accumulates in the brain.<sup>18</sup>

Mercury has a number of mechanisms leading to toxicity in biological systems. These include the following:

- Breaking of hydrogen bonds.
- Displacement of other metallic ions from a ligand site.
- Change in tertiary protein structure, leading to inhibition of catalytic activity.
- Attachments of ligands to cell membranes, leading to inhibition or acceleration of permeability selection.
- Alteration of translational processes, leading to mutagenic and carcinogenic activity. Inhibition of DNA repair enzymes.<sup>19</sup>

Changes in the tertiary structure of a protein can lead to the inhibition of enzymatic activity,<sup>19</sup> possibly one of the factors causing the changes found in this study. Mercury, which has a strong affinity for sulfur-based (sulfhydryl) bonds, has the potential to bind to similarly configured sites in myelin proteins. These sites include sulfhydryl groups, disulfide bridges, lipoproteins, glycoproteins, and half-cysteine residues.<sup>20</sup> The binding of mercury to both lipoproteins in the CNS and half-cysteine residues in the peripheral nervous system is of particular interest, since many of the typical symptoms seen in MS involve both of these systems.

Mercury is unevenly distributed in the brain and spinal cord, with the heaviest deposits found within the motor nuclei of the rhombencephalon. A disproportionately high amount of mercury is found in the anterior horn motor neurons, which innervate the skeletal muscles. The heaviest mercury accumulations in the CNS, at least in animal studies, are seen in those primary motor regions of the brain stem and cerebellum.<sup>21</sup> These sites of mercury accumulation in the CNS support a possible

link between mercury and MS because of the preponderance of motor rather than sensory symptomatology in the advanced MS patient. Mercury's strong predilection to accumulate in the neuroglial cells further supports this thesis. Pathologically, MS is characterized by overgrowths of these same neuroglial cells (gliosis), sometimes as tumors.

Gliomas, tumors of neuroglial cells, are known to express over a hundred antigens.<sup>22</sup> Cultured gliomas, however, have a markedly low expression of antigens. Mercury is known to accumulate in the neuroglial cells and its high avidity for cellular protein could be a factor in the stepped-up production of antigens seen in gliomas *in vivo*. Mercury is already implicated in autoimmune disease, possibly through such a prolific production of antigenic material.<sup>22</sup>

Another entrance route of mercury into the CNS has recently been described in animal studies.<sup>23</sup> This route *directly* implicates amalgam as a likely source of CNS mercury exposure. Retrograde axonal transport has been documented as a valid mechanism for the introduction of various agents into the CNS.<sup>23</sup> Similarly, mercury from amalgam in humans may well be able to utilize such a means of access, which would circumvent the blood-brain barrier in reaching the nervous tissues of the CNS. This could also allow non-elemental forms of mercury to reach the CNS directly. Mercury from amalgam fillings has been identified in the dental pulp. Other investigators have already suggested mercury might be transported retrogradely from the dental pulp to the trigeminal ganglion.<sup>24,25</sup> In these studies, injected mercury was observed in the trigeminal ganglion ipsilateral to the injection. No mercury was seen in the contralateral ganglion. It was concluded that the accumulation of mercury in neurons of the trigeminal ganglion was the result of retrograde axonal transport in neurons originating in the tooth pulp.<sup>24</sup>

Mercury is released from amalgam restorations, especially during mastication, and a correlation has been found between the number of tooth surfaces containing amalgam and the concentration of mercury in the occipital cortex<sup>24</sup> and total brain.<sup>26</sup> The dorsal root ganglia (of interest in MS) have been found to accumulate larger amounts of mercury than any other part of the nervous system.<sup>27</sup>

In this study, distinct electrophoretic bands of CSF proteins are detected in patients prior to their dental amalgam removal. A dramatic reduction in photolabeling of these proteins is seen within 48 hours after completion of the treatment protocol. Due to difficulty with patient access, later and repeated CSF examinations could not be obtained. As mercury binds so avidly to CNS tissues and is known to induce autoimmune processes elsewhere in the body, chronic mercury exposure might be suspected in the etiology of multiple sclerosis.

## Conclusion

This preliminary study demonstrated that the present protocol of removal of dental amalgam in concert with the other multiple aspects of our clinical treatment protocol rapidly and consistently changed the photolabeling characteristics of CSF proteins in MS patients. However, no direct and unassailable conclusions as to the etiology of MS can be reached solely from this data. Mercury has been documented to accumulate in the very areas of the nervous system from which the most dramatic clinical symptoms of MS originate. Specifically, motor neurons accumulate more Hg than sensory neurons, and motor symptoms are seen to predominate over sensory symptoms in MS. Although more research needs to be done in this area, these results suggest dental mercury exposure from amalgams, as well as from any other chronic low-grade mercury exposure, might be given

consideration as possibly playing a role in the etiology of MS in these patients.

## Acknowledgments

Dr. Huggins and Dr. Levy extend recognition, acknowledgment, and thanks to Dr. Boyd Haley and his laboratory at the University of Kentucky Medical Center for performing the gel electrophoresis on the cerebrospinal fluid samples.

## References

1. Ingalls T. Epidemiology, etiology, and prevention of multiple sclerosis. Hypothesis and fact. *Am J Forensic Med Pathol* 1983;4:55-61.
2. Ingalls T. Endemic clustering of multiple sclerosis in time and place, 1934-1984. Confirmation of a hypothesis. *Am J Forensic Med Pathol* 1986;7:3-8.
3. Craelius W. Comparative epidemiology of multiple sclerosis and dental caries. *J Epidemiol Community Health* 1978;32:155-165.
4. Baasch E. Theoretical considerations on the etiology of multiple sclerosis. Is multiple sclerosis a mercury allergy? *Schweiz Arch Neurol Neurochir Psychiatr* 1966;98:1-19. [Article in German]
5. Clausen J. Mercury and multiple sclerosis. *Acta Neurol Scand* 1993;87:461-464.
6. Siblingrud R, Kienholz E. Evidence that mercury from silver dental fillings may be an etiological factor in multiple sclerosis. *Sci Total Environ* 1994;142:191-205.
7. Siblingrud R. A comparison of mental health of multiple sclerosis patients with silver/mercury dental fillings and those with fillings removed. *Psychol Rep* 1992;70:1139-1151.
8. Le Quesne P. Metal-induced diseases of the nervous system. *Br J Hosp Med* 1982;28:534-538.
9. Svare C, Peterson L, Reinhardt J, et al. The effect of dental amalgams on mercury levels in expired air. *J Dent Res* 1981;60:1668-1671.
10. Price W. *Dental Infections Oral and Systemic*. Cleveland, OH: Penton Publishing Company; 1923.
11. Price W. *Dental Infections and the Degenerative Diseases*. Cleveland, OH: Penton Publishing Company; 1923.
12. Laemmli U. Cleavage of structural proteins during the assembly of the head of bacteriophage T4. *Nature* 1970;227:680-685.
13. Grundke-Iqbal I, Iqbal K, Tung Y, et al. Abnormal phosphorylation of the microtubule-associated protein tau (tau) in Alzheimer cytoskeletal pathology. *Proc Natl Acad Sci U S A* 1986;83:4913-4917.
14. Mantyla D, Wright O. Mercury toxicity in the dental office: a neglected problem. *J Am Dent Assoc* 1976;92:1189-1194.
15. Shapiro IM, Cornblath DR, Sumner AJ, et al. Neurophysiological and neuropsychological function in mercury-exposed dentists. *Lancet* 1982;22:1147-1150.
16. Halberg H. *Chronobiology—Principles and Applications to Shifts and Schedules*. The circadian time structures. NATO Advanced Study Inst. Series D. Sijthoff, International Pub., Leider, Netherlands, 1980.
17. Friberg L. Environmental Health Criteria 118, Inorganic Mercury, World Health Organization, 1991.
18. Clarkson T. Metal toxicity in the central nervous system. *Environ Health Perspect* 1987;75:59-64.
19. Friberg L, Gunnar F, Nordberg V, Velimir B. *Handbook on the Toxicology of Metals. Vol. I*. New York, NY: Elsevier Science Publishing; 1986:138.
20. Ganser A, Kirschner D. The interaction of mercurials with myelin: comparison of in vitro and in vivo effects. *Neurotoxicology* 1985;6:63-77.
21. Moller-Madsen B, Danscher G. Localization of mercury in CNS of the rat. I. Mercuric chloride (HgCl<sub>2</sub>) per os. *Environ Res* 1986;41:29-43.
22. McKeever P, Davenport R, Shakui P. Patterns of antigenic expression of human glioma cells. *Crit Rev Neurobiol* 1991;6:119-147.
23. Arvidson B. Accumulation of mercury in brainstem nuclei of mice after retrograde axonal transport. *Acta Neurol Scand* 1990;82:234-237.
24. Arvidson B, Arvidsson J. Retrograde axonal transport of mercury in primary sensory neurons innervating the tooth pulp in the rat. *Neurosci Lett* 1990;115:29-32.
25. Moller B. Reaction of the human dental pulp to silver amalgam restorations. Mercury determination in the pulp by flameless atomic absorption spectrophotometry. *Swed Dent J* 1978;2:93-97.
26. Danscher G, Horsted-Bindslev P, Rungby J. Traces of mercury in organs from primates with amalgam fillings. *Exp Mol Pathol* 1990;52:291-299.
27. Schionning J, Poulsen E, Moller-Madsen B, Danscher G. Ultrastructural localization of mercury in rat dorsal root ganglia after exposure to mercury vapor. *Prog Histochem Cytochem* 1991;23:249-255.