

# JCCP

---

## JOURNAL OF CLINICAL CHIROPRACTIC PEDIATRICS



VOLUME 12 • NO. 2 • DECEMBER 2011

PUBLICATION OF THE COUNCIL ON CHIROPRACTIC PEDIATRICS  
INTERNATIONAL CHIROPRACTORS ASSOCIATION

# JCCP JOURNAL OF CLINICAL CHIROPRACTIC PEDIATRICS

---

## EDITORS

**Sharon Vallone, DC, FICCP**

**Cheryl Hawk, DC, PhD**

---

## EDITORIAL REVIEW BOARD

**Marion Willard Evans, Jr.,**

**DC, PhD, MCHES**

Texas Chiropractic College, Pasadena, Texas

**Peter N. Fysh, DC, FICCP**

San Jose, California

**Alison K. Hazelbaker, MA, PhD, IBCLC**

Columbus, Ohio

**Anupama Kizhakkeveetil,**

**BAMS (Ayurveda), MAOM, Lac**

Southern California

University of Health Sciences

Whittier, California

**Dana J. Lawrence, DC, MMedEd, MA**

Palmer College of Chiropractic

Davenport, Iowa

**Robert A. Leach, DC, MS, CHES**

Starkville, Mississippi

**Maxine McMullen, DC, FICCP**

Port Orange, Florida

**Stephanie O'Neill-Bhogal, DC, DICCP**

Palmer College of Chiropractic

Davenport, Iowa

**Mart T. Pfefer, RN, MS, DC**

Cleveland College of Chiropractic

Overland Park, Kansas

**Katherine A. Pohlman, DC, MS, DICCP**

Palmer Center of Chiropractic Research

Davenport, Iowa

**Molly Ranganath, MA**

Falls Church, Virginia

**Richard Strunk, DC, MS**

Cleveland College of Chiropractic

Overland Park, Kansas

**Lora Tanis, DC, DICCP**

Hewitt, New Jersey

**Meghan Van Loon, PT, DC, DICCP**

New York College of Chiropractic

Seneca Falls, New York



The Journal of Clinical Chiropractic Pediatrics (JCCP) is the official peer-reviewed journal of the Council on Chiropractic Pediatrics, 6400 Arlington Boulevard, Suite 800, Falls Church, Virginia 22042, U.S.A. Printed and mailed in Virginia, U.S.A.

Copyright by the Council on Chiropractic Pediatrics. All rights reserved. Reproduction or translation of any part of this work beyond that permitted by Section 107 or 108 of the United States Copyright Law without permission of the copyright owner is unlawful. Printed in the United States.

**Editorial Correspondence:** Editorial correspondence should be sent to the Editor, JCCP, ICA Council on Chiropractic Pediatrics, 6400 Arlington Boulevard, Suite 800, Falls Church, Virginia 22042, U.S.A. Email: [peditriaticscouncil@chiropractic.org](mailto:peditriaticscouncil@chiropractic.org) or [svallonedc@aol.com](mailto:svallonedc@aol.com)



---

# JCCP JOURNAL OF CLINICAL CHIROPRACTIC PEDIATRICS

---

VOLUME 12, NUMBER 2

DECEMBER, 2011

---

**Guest Editorial: The First Pediatric Mentored Research Competition** ..... 901  
*Katherine Pohlman, DC, MS, DICCP*

**Resolution of Conductive Hearing Loss Due to Otitis Media after Chiropractic Treatment** ..... 903  
*By Peri Dwyer, DC, DICCP and James Boysen, DC*

**Chiropractic Care for Postpartum Pelvic Girdle Pain and Low Back Pain: A Case Report** ..... 910  
*Karen Gregory, BAppSc (Chiro) and Robert Rowell, DC, MS*

**Joint Hypermobility Syndrome: Which Intervention?** ..... 915  
*Joyce E. Miller, BSc, DC, DABCO, FCC and Sally L. Mathews, BSc(Hons)*

**Benefits of Chiropractic Care of an Infant Demonstrating Congenital Myogenic Ptosis: A Case Study** ..... 919  
*Jennifer T. Murphy, DC, DICCP and Casey Crisp, DC, MS*

**Improvement of Chronic Constipation in a 5-Year-Old Female after Chiropractic Treatment** .... 925  
*Carol Parnell, DC, DICCP and Amin Nekoomand, DC*

**Chiropractic Care of Infant with Down Syndrome: A Case Report** ..... 927  
*Rachael A. Kuperus, DC, Rebekah A. Wittman, DC, DACCP and Sharon Vallone, DC, FICCP*

**Abstracts of Interest** ..... 935



PUBLISHING OFFICES:

ICA COUNCIL ON CHIROPRACTIC PEDIATRICS  
6400 Arlington Boulevard, Suite 800  
Falls Church, Virginia 22042 U.S.A.

Phone: 703-528-5000  
Fax: 703-351-7893

# JCCP JOURNAL OF CLINICAL CHIROPRACTIC PEDIATRICS

The *Journal of Clinical Chiropractic Pediatrics* welcomes original and scholarly manuscripts for peer-review and consideration for publication. Topics must pertain to the field of pediatrics which includes pregnancy and adolescence. Manuscripts should not have been published before or submitted to another publication.

## The following will be considered:

**Case Reports and Case Series** — presentations of individual or groups of cases deemed to be of interest to the professional and scholarly community.

**Pilot Studies or Hypothesis** — papers which, while very broad, present with a clear hypotheses and suggest a foundation for future, in-depth studies.

**Literature Reviews** — studies of existing papers and books presented with the intention of supporting and encouraging new and continuing study.

**Technical Descriptions** — reports of new analytical/diagnostic tools for assessment and delivery of care.

**Controlled, Large Scale Studies** — usually, but not necessarily, performed at a college or research facility. May be double-blinded.

**Commentaries** — presentations of opinion on trends within the profession or current events, pertaining to pediatric and adolescent chiropractic care.

## Guidelines for submission

All manuscripts are accepted purely for consideration. They must be original works and should not be under consideration by any other journal or publisher at the time of submission. They *must* be accompanied by a TRANSFER OF COPYRIGHT form, signed by all authors and by the employer if the paper is the result of a “work for hire.” It is understood that while the manuscript is under consideration it will not be sent to any other publication. In the case of multiple authors, a transmittal letter should designate one author as correspondent.

Manuscripts may be sent electronically (preferred) to [peditricscouncil@chiropractic.org](mailto:peditricscouncil@chiropractic.org), or on a CD (with one hard copy) by mail to JCCP, 6400 Arlington Boulevard,

Suite 800, Falls Church, Virginia 22042, USA. Manuscript should be in document style MS Word (or compatible) and unformatted.

The *first page* of the manuscript must contain:

1. The title of the paper
2. The first name, middle initial and last name of each author, with highest academic degree(s)
3. Names of departments and institutions to which the work should be attributed (if any)
4. Name, address and phone number of author responsible for correspondence
5. Source of funding (e.g. grants, self-funded, etc.)
6. Conflict of interest if any
7. Source of any support (e.g. equipment, organizations, individuals, etc.)

The **paper** must include an **abstract** or **summary**. This abstract/summary should state the purpose of the paper (objective), procedures, methods, main findings (results) and principal conclusions. Also, any key words or phrases that will assist indexers should be provided.

**References** must be cited for all materials derived from the works of other people and previously published works. Reference numbers must be assigned in the order of citation in the paper. References should follow the following format:

*From journals* —

Gorman JF. Automatic static perimetry in chiropractic. *J Manipulative Physiol Ther* 1993; 16(4):481-7.

*From books* —

Gatterman MI. Chiropractic management of spine related disorders. Baltimore: Williams & Wilkins; 1990.

**Tables** — Each table or figure should be on a separate page and not imbedded in the manuscript. If the table is from another publication, permission to publish must be granted and the publication acknowledged.

**Photographs** — Photographs should be scanned in gray-scale at 300dpi with sharp contrast.

**Informed Consent** — If the research/study involves

---

experimental investigations performed on humans the manuscript must include a statement that informed consent was obtained from the individuals involved in the investigation.

**Patient Anonymity** — Patient names or any information that could identify a specific patient should be avoided. Photographs accompanying a manuscript must have a consent form signed by the individual or parent or guardian in the case of a minor. These are to include any requests for blocking faces, etc.

**Acknowledgements** — Any illustrations from other publications must be acknowledged. It is the author's responsibility to obtain written permission from the publisher and/or author for their use.

All manuscripts deemed appropriate for publication by the editor will be sent *blind* to at least two reviewers. If the manuscript is accepted, the author will be notified. If substantive changes are required, the paper will be returned to the author and the author must re-submit a clean copy of the revised manuscript. Author will be given a tentative

date for publication if accepted.

Manuscripts not accepted for publication will be returned to the author without comment.

### Summary of manuscript submission

1. Manuscript (digital in MS Word unformatted)
2. Illustrations/Diagrams (scanned at 100% in high resolution 300dpi)
3. Photographs (digital JPEG or TIFF 300dpi)
4. Transfer of copyright form signed by all authors.
5. Consent form for photographs (if applicable)
6. Letters of permission to use previously published materials (if applicable).
7. Cover letter from principal author (or author designed as correspondent) providing any special information regarding the paper that may be helpful in considering it for publication.
8. Digital files to be sent to [svallonedc@aol.com](mailto:svallonedc@aol.com).





## The First Pediatric Mentored Research Competition

What does it take to move this profession forward? Action! Who takes action! Inspired and committed individuals like our guest editorialist — Dr. Katherine Pohlman. To encourage field practitioners who feel challenged in their ability to communicate their clinical experiences with colleagues, Dr. Pohlman found a creative way to support their efforts through a mentoring program. As it turned out, this not only helped the practitioner but also the mentor who may have the expertise in scientific writing and critical thinking but does not always have the information gleaned from actual practice. Collaboration between field practitioners and researchers is not as hard as we imagine and hopefully inclusion in several studies is not too far off in the future or out of our reach. I look forward to that day when we see this type of collaboration result in papers that we can publish in this journal.

**Sharon Vallone, DC, FICCP**  
Co-Editor  
Journal of Clinical Chiropractic Pediatrics

---

The first Pediatric Mentored Research Competition was inspired by a scientist, a chiropractic faculty member, and a pediatric chiropractor discussing certain literature gaps. This discussion was quite different than most: it was focused on what could be done about these gaps, rather than just its existence. We concluded that pediatric chiropractors with cases to write up should team up with mentors that have scientific writing experience. Throughout history, mentors have been an invaluable asset to one's growth. Pre-historic children in primitive dwellings learned their skills from their parents with the expectation that they would enhance their chances of survival. In the academic world, however, general instruction does not fully provide the personal contact through which information of importance is transferred. What is needed is the one-to-one learning environment that a mentorship relationship provides. Having an extra hand to help out has sometimes been just enough for one to overcome a particular fear or challenge. This is exactly the case with this first competition.

After a call for topics was sent out to all graduates of and currently students enrolled in the Diplomate in Clinical Chiropractic Pediatrics (DICCP) program, 14 topics emerged. Of these 14 topics, 12 practitioners were teamed up with mentors. The 12 mentors were selected from the Palmer College of Chiropractic who chose their mentees by their topics. A wiki was initially set up for each team's use to help with version control and file sharing via email, but this ended up being more problematic for some more than others, thus many teams found their own modes of communication. From the 12 initial teams a total of 10 papers were submitted approximately 8 months after initial introductions. These 10 papers were all provisionally accepted to the *Journal of Clinical Chiropractic Pediatrics* (JCCP), four of which are included in this issue while others will be in subsequent issues.

The 10 initial submissions were graded by three reviewers using a standardized rubric. The authors of the top five papers were asked to give an 8-minute presentation at the first Joint Pediatric Conference held in Oahu, Hawaii, December 9-11, 2011. All authors were also asked to display a poster presentation at the conference. From September until early December, all authors received feedback from their mentors, and revised their papers as necessary. They then prepared their oral and poster presentations. All of these items required tremendous effort and the papers and presentations, the outcomes of this mentor project, were a demonstration of the authors' perseverance and commitment to the pediatric chiropractic profession.

As I reflect upon this exciting event that occurred in just a small amount of time, I am inspired with the future of pediatric chiropractic research. I want to thank everyone involved with this project: the committee, the mentors and the mentees. You have each made a huge contribution to the state of pediatric chiropractic scientific literature. Thank you.

**Katherine A. Pohlman, DC, MS, DICCP**  
Guest Editor





# Resolution of Conductive Hearing Loss Due to Otitis Media after Chiropractic Treatment

Peri Dwyer, DC, DICCP and James Boysen, DC

## ABSTRACT

**Objective:** To describe the chiropractic management of a patient with otitis media and conductive hearing loss.

**Clinical Features:** Parents of a 6-year-old male sought chiropractic care for the child's measured conductive hearing loss on pure-tone audiometry, fluid in both ears and repeated bouts of otitis media. Prior treatment included several rounds of antibiotics starting at 14 months and myringotomy at age 3.

**Intervention And Outcome:** Treatment consisted of cervical, thoracic and pelvic manual manipulative therapy along with cranial manipulation. After 6 chiropractic adjustments, the child was asymptomatic, and remained free of otitis media symptoms on long-term follow-up. Nineteen months after commencement of treatment, a repeat audiogram was performed, showing normal hearing in both ears.

**Conclusion:** A 6-year-old male with recurring otitis media and conductive hearing loss was successfully managed using chiropractic adjustments. This may suggest a role for chiropractic care the management of otitis media with conductive hearing loss. Further research is necessary to examine this in more detail.

**Key Words:** Otitis media, audiology, chiropractic, therapy, child, manipulation

## Introduction

Ten million office visits in the United States are associated with otitis media (OM).<sup>1</sup> The economic burden in the US is estimated at \$108 to \$1,300 per episode.<sup>2</sup> Total cost of otitis-associated disease in the US is \$3.8 billion annually: \$1.8 billion in medical costs; and \$2.0 billion in parental time costs.<sup>3</sup> Mean time-off hours lost of caregivers in 7 European countries ranged from 17.3 to 35.1 while mean productivity lost ranged from 6.7 to 22.7 hours.<sup>4</sup>

According to O'Reilly, risk factors include: young age, functional immaturity of the Eustachian tube, group child care, season of the year, lack of breastfeeding, the presence of adenoid tissue, environmental smoke exposure, pacifier use, allergy, sibling order, craniofacial abnormalities, genetic predisposition, and ethnicity.<sup>5</sup> Exposure to dioxin-like compounds and air pollution, as well as preterm birth, socioeconomic status and overweight status are also associated with OM.<sup>2,6-9</sup> OM in its broadest sense is simply inflammation of the middle ear. In common usage, the word is used as synonymous with "ear infection," even by many physicians, but the condition which most chiroprac-

tors confront in pediatric patients, persistent middle ear effusion (MEE) involves no culturable pathogenic bacteria in 75% of patients.<sup>10</sup>

There are 3 major categories of otitis media:

**Acute otitis media (AOM):** Oski's Principles and Practice of Pediatrics (1994, JB Lippincott, Philadelphia) defines this as "suppurative middle ear infection of relatively sudden clinical onset." Otoscopy is the diagnostic hallmark, and the condition is defined by a "hyperemic, opaque tympanic membrane with distorted or absent light reflex and indistinct landmarks". Of children with a red or yellow tympanic membrane and distention and absence of visible landmarks on otoscopy, 91% will have a bacterial infection of the middle ear.<sup>11</sup> Many studies have demonstrated that the majority of these infections resolve well without treatment, and that comparing antibiotic treatment to placebo reveals a very slight difference, or no difference, in the recovery rate from the acute, symptomatic episode.<sup>10</sup>

**Otitis media with effusion (OME):** This is the pediatric condition most often evaluated by audiology. The presence of effusion is generally believed to be due to a pressure gradient formed by the microvascular resorption of nitrogen from the middle ear in the absence of a patent Eustachian tube. This results in decreased pressure (and often a retracted tympanic membrane), causing extracellular fluid to exude into the middle ear cavity.<sup>11</sup> However, the presence of OME cannot be diagnosed by inspection of

**Peri Dwyer, DC, DICCP**

*Private practice, Tallahassee, Florida, USA*

**James Boysen, DC**

*Palmer Center for Chiropractic Research, Davenport, Iowa, USA*

*Corresponding author:*

*Dr. Peri Dwyer: Phone: 850-877-8990; Fax: 850-671-1796*

the tympanic membrane alone. Pneumatic otoscopy and/or tympanometry is necessary to assess the mobility of the tympanic membrane.<sup>12</sup> The prevalence of OME accounts for 25% to 35% of all otitis media.<sup>13</sup> Williamson stated that by 4 years of age, 80% of children have been affected by OME and the prevalence declines after age 6.

Middle ear effusion (MEE): Finally, there may exist a condition in which the patient is asymptomatic and afebrile, but has continued presence of fluid and evidence of a non-functional Eustachian tube. The criteria for a diagnosis of MEE are either:

1. Two of the 3 findings:
  - a. membrane opacity;
  - b. color change/fullness; and
  - c. impaired mobility; or
2. Direct visualization of an air-fluid level.<sup>10</sup>

Up to 60% of children who have AOM will have persistent MEE 14 days after the bacteria have been eradicated.<sup>14</sup>

AOM is the most frequently diagnosed condition in children and the most common reason for antibiotic therapy.<sup>15</sup> Eighty percent of AOM resolves in 3 days without treatment and watchful waiting has been advised by the American Academy of Pediatrics and the American Academy of Family Physicians (AAP-AAFP) as a viable approach for children 2-12 years old with non-severe, uncomplicated AOM. The AAP-AAFP recommends antibiotic therapy for younger children or those with recurrent AOM.<sup>16</sup> Antibiotic use may include adverse events such as GI upset, destruction of the gut's natural flora (which may lead to thrush), allergic reactions, increased microbial resistance to antibiotics and cost.<sup>17</sup>

### Complications of Otitis Media

Complications of OM may include: tympanic membrane perforation, tympanosclerosis, otorrhea, or cholesteatoma.<sup>13</sup> Sequelae of OM may include: hearing loss (most commonly conductive); developmental delays in language, behavior, and education; mastoiditis; facial nerve paralysis; vestibular, balance and motor dysfunction; and meningitis.<sup>18</sup> In older children increased aggressiveness and rule-breaking behavior have been reported.<sup>19</sup> Tinnitus in adults is associated with a history of childhood OM.<sup>20</sup>

### Treatment Options

Treatment of OM includes antibiotics, prophylactic

antibiotics, vaccination, myringotomy with/without insertion of tympanostomy tube, and/or adenoidectomy with or without tonsillectomy.<sup>18</sup>

Surgical treatment with tympanostomy tubes is widespread yet controversial. A Cochrane review concluded tympanostomy tubes for hearing loss associated with otitis media with effusion were mainly beneficial in the first 6 months after insertion, although the benefits were small and diminished over time.<sup>21</sup> This study did not find any benefit to speech, language, learning or developmental problems, but no study has been performed on children who have established deficits in these areas.

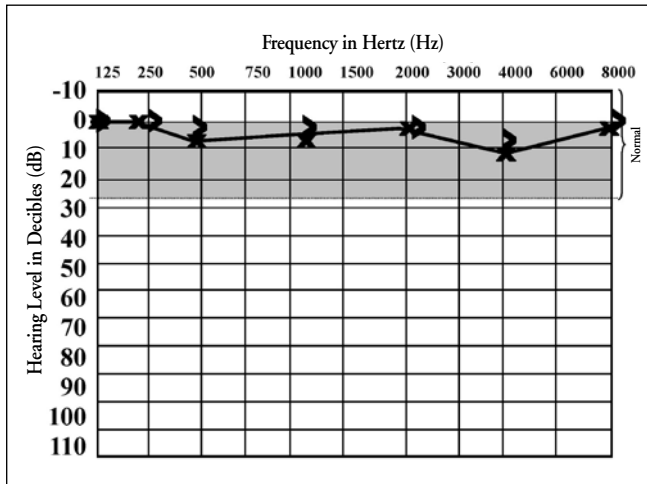
Williamson concluded that "Oral antibiotics, antihistamines plus oral decongestants, or mucolytics may be of no benefit in OME and can cause adverse effects", "Ventilation tubes may improve short-term outcomes, but the clinical effect size is small" and "Ventilation tubes improve hearing for the first two years, but have no longer-term benefit, and may not improve cognition of language."<sup>13</sup> Tympanostomy-tube insertion is the most frequently performed operation in children in the US.<sup>3</sup>

### Audiometry

The great concern when a child has recurrent OME or chronic MEE is that the child's language development may be compromised due to hearing loss.<sup>22</sup> In children 5 years of age or older, the most reliable method of determining hearing loss is by pure-tone audiometry. When the hearing is below the depicted normal range in one or more frequencies, it is given the following grade:

- -10dB to 25dB = Normal range
- 26dB to 40 dB = Mild hearing loss
- 41 dB to 55 dB = Moderate hearing loss
- 56 dB to 70 dB = Moderately Severe hearing loss
- 71 dB to 90 dB = Severe hearing loss
- over 90 dB = Profound hearing loss.

If the hearing loss is less than normal, it becomes necessary to determine if the hearing loss is sensorineural (due to loss of function in the cochlea, 8th cranial nerve, or brain), or conductive (due to interruption of sound in its travel from the external ear canal, through the malleus, incus, and stapes of the middle ear, and into the cochlea). This is done by comparing bone conduction to air conduction. A loss only in air conduction would be diagnostic of conductive hearing loss, while combined bone and air conduction loss would be diagnostic of sensorineural hearing loss (*Figure 1*).



**Figure 1. Normal audiogram**

When an air-bone gap (conductive hearing loss) is present, MEE is present 86-100% of the time.<sup>23</sup> When the pressure is artificially equalized between the middle ear and the nasopharynx or between the middle ear and the outside world, this air-bone gap reduces immediately but temporarily in over 90% of cases (Figure 2).<sup>24,25</sup>

### Case Report

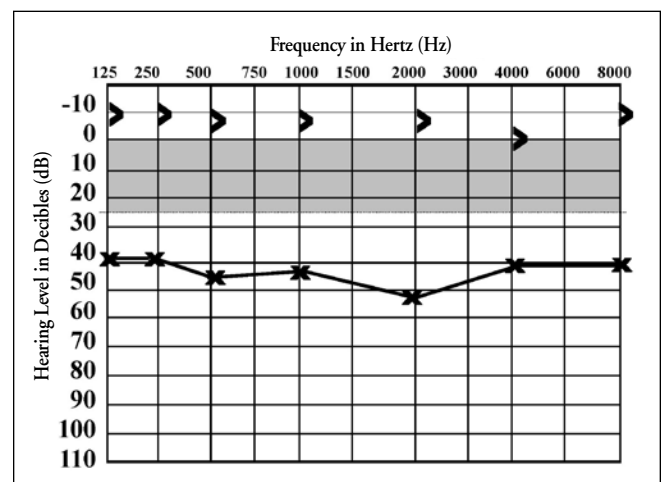
Parents of a 6-year-old male sought care for fluid in both ears for “quite a while”. They also reported concern about hearing loss as measured by audiometry ordered by an ENT specialist. History revealed recurrent ear infections beginning at the age of 14 months. He was initially treated with repeated courses of antibiotics, and then by insertion of myringotomy tubes at age 3. These tubes extruded spontaneously at about age 5. Prior to seeking chiropractic care, he had recently completed a course of antibiotics for an episode of AOM. When the condition did not appear to resolve, his ENT recommended repeat tube insertion. History included several risk factors for otitis media, including short duration of breastfeeding, parental smoking, and early day care. His initial audiogram was performed at a separate facility 9 days before starting chiropractic treatment, at the age of 6 years, 7 months (Figure 3). The test showed an obvious air-bone gap, with conductive hearing loss greater on the left than on the right. Examination of this well-nourished white male child showed postural distortion in the form of a right head tilt, restricted cervical ranges of motion and spinal subluxations/fixations of multiple segments. Multiple enlarged cervical and submandibular lymph nodes were palpable.

Treatment consisted of 6 chiropractic manipulations utilizing Gonstead and Diversified high-velocity low-

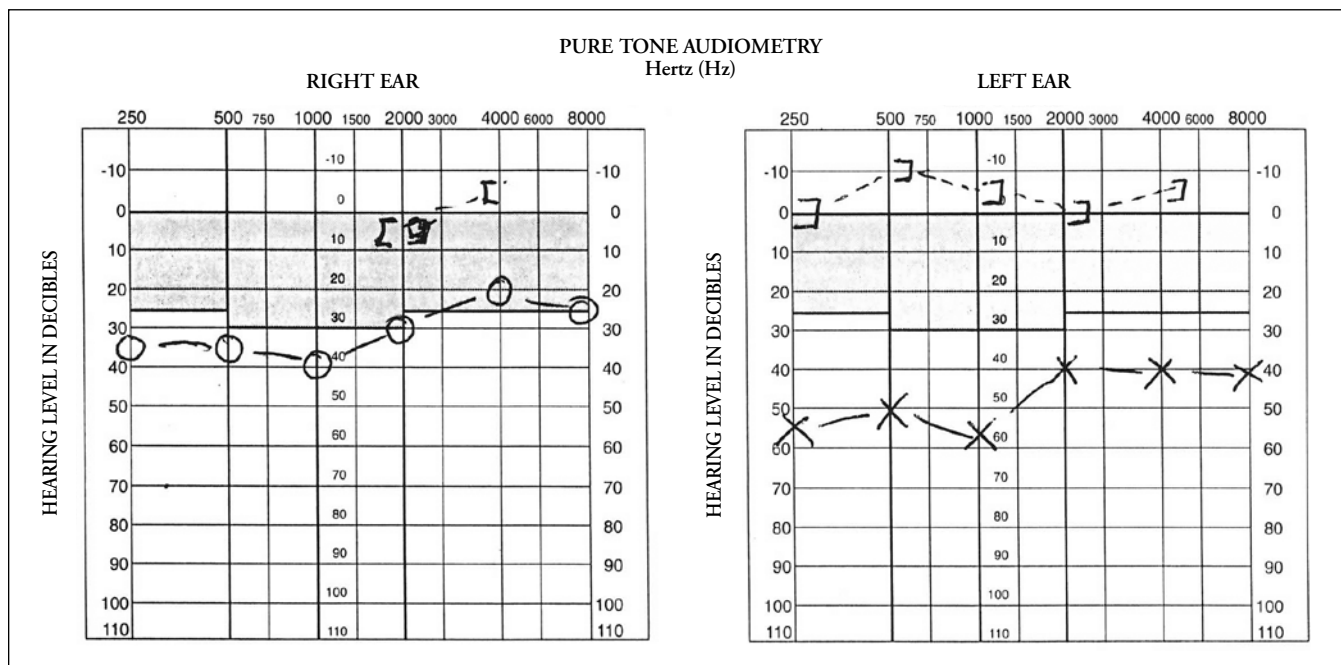
amplitude techniques modified to use fingertip contacts and lower force for pediatric application. Segments adjusted were based on static and motion palpation of the entire spine, and no attempt was made to correlate the segments adjusted with the segmental innervation of the middle ear or Eustachian tubes. No dietary changes were advised, and the risk factor of household smoking was not changed. The treatments were applied on a gradually tapering basis over the course of 22 days.

A brief summary of the notes from clinical encounters and treatment follows:

- **Day 1:** See the initial history and exam findings above. Chiropractic manipulative therapy (CMT) consisted of the following: C1 right supine rotatory; C6 left supine rotatory; T4 and T10 prone double-contact diversified; right sacroiliac side posture.
- **Day 6:** Patient reported that he heard things “louder” immediately after last visit. Right tympanic membrane (TM) showed fluid and was immobile on insufflation, but was glossy. The left TM showed no fluid and was mobile but had some dullness. Lymph node enlargement was more pronounced on the right. CMT consisted of C1 right supine rotatory; C5 right supine rotatory; T7 prone double-contact diversified; and Sacro-Occipital Technique craniopathy.
- **Day 9:** “Hearing better” as reported by the patient’s father. The right TM was mobile with no fluid and some dullness; the left TM was dull with increased fluid but was mobile. CMT was C1 right supine rotatory, C5 left supine rotatory, T7 prone double-contact



**Figure 2. Example of audiogram showing significant air (>) - bone (x) gap.**



**Figure 3. Pre-chiropractic treatment: 9 days prior to treatment showing mild to moderate conductive hearing loss.**

diversified, and Applied Kinesiology cranial.

- **Day 14:** Hearing continues intermittently better per patient and per informal observations by father. TMs both were observed as dull/opaque/fluid-filled and non-mobile. Head and body posture improved. Assessment was: fair-poor results with tympanic problem and good results with subluxations/mechanical derangement. CMT was C1 right supine rotatory and T8 double-contact diversified.
- **Day 22:** Left TM mobile with no fluid; right TM mobile with fluid seen. CMT was C3 or C4 (the note is ambiguous) right supine rotatory only.
- **Day 27:** Hearing “up and down” per father. TM’s bilaterally had no fluid and were mobile on insufflation. There was slight erythema of the left middle ear visible through the tympanic membrane. The patient’s cervical spine was free of palpable chiropractic subluxations. CMT was T9 prone diversified, left sacroiliac side-posture.

The patient had no ear pain or drainage and his hearing subjectively seemed improved at the end of the treatment, and the parents chose to cancel the surgery. The child remained asymptomatic with no further chiropractic or medical treatment. When the child was age 8 years, 2 months, a repeat audiogram was performed at the same separate audiology facility (19 months after his initial

audiogram and 18 months after completing chiropractic treatment). Results showed the patient’s air-bone gap had closed completely, and the hearing in both ears was within normal limits (*Figure 4*).

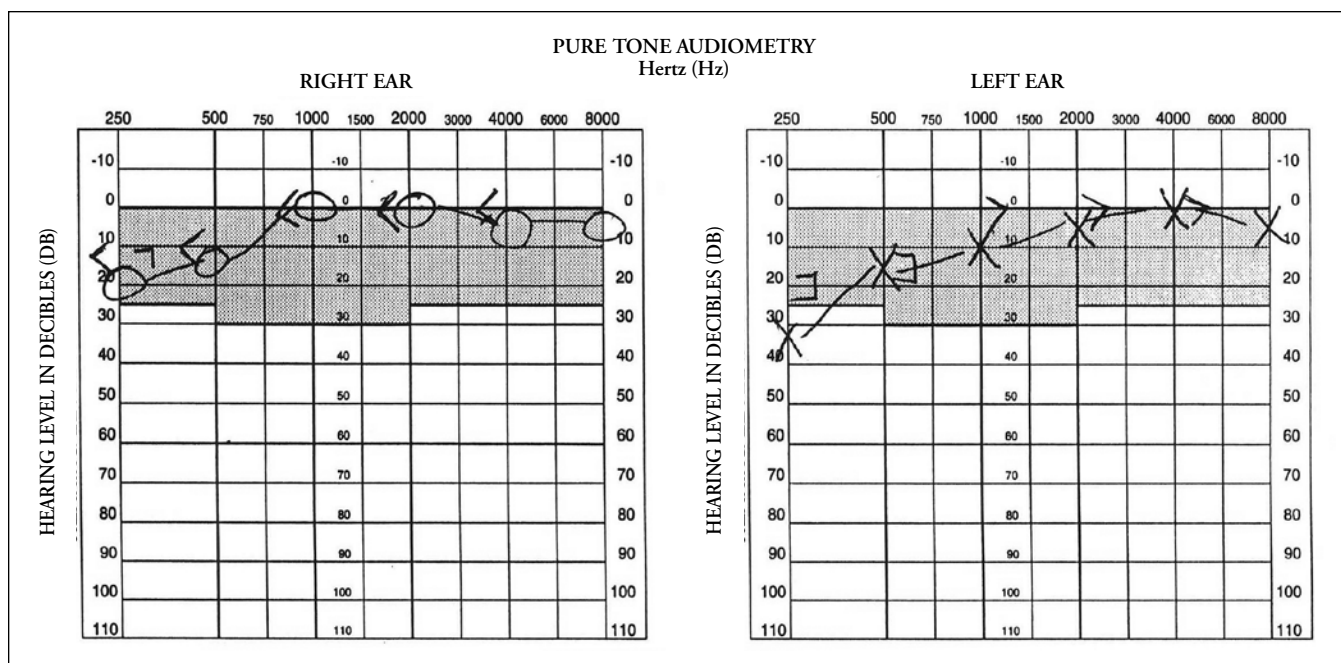
### Discussion

#### Chiropractic non-manipulative interventions

Treatment or prevention available to the chiropractor may include: xylitol as a preventative; precautions against reflux by avoiding chocolate, acidic or fruit juices, tomatoes, and fatty or greasy food, and not eating before bedtime.<sup>9,26</sup> Hand washing reduces URTI which may also decrease OM.<sup>22</sup> Zinc supplements for preventing otitis media found no convincing evidence in a Cochrane review.<sup>27</sup>

#### Manipulation’s effects on OM

Manipulation evidence for OM has been mixed. A review of the effectiveness of manual therapies on otitis media found the evidence to be inconclusive.<sup>28</sup> Another review found that there is little current evidence to support chiropractic care for improvement of AOM.<sup>29</sup> However, Hawk’s et al. systematic review of chiropractic for nonmusculoskeletal conditions found 1 random controlled trial (RCT), 3 case series, 3 case reports and 1 pilot study for evidence of chiropractic care for otitis media. The RCT was found to be of “high” quality and found significantly fewer surgical procedures compared to usual medical care.<sup>30</sup> Since Hawk’s



**Figure 4. Post-chiropractic treatment:  
19 months later showing near normal hearing.**

2007 review, two additional case studies on otitis media with hearing loss have been reported in children.<sup>31,32</sup>

The prevalence for otitis media decreases after 6 years of age, which is the approximate age of cranial vault maturity<sup>18</sup> (Although the subject of this paper had persistent symptoms after reaching the age of 6). This, along with craniofacial abnormality as a risk factor and the fact that myringotomy with tympanostomy tube insertion affords symptomatic relief, suggests that a dysfunctional eustachian tube plays a large role in OM. The adult eustachian tube is larger, contains more elastin and traverses 45 degrees from the temporal bone to the nasopharynx, compared to the child's smaller eustachian tube with less elastin that traverses 10 degrees.<sup>18</sup>

The mechanism of theorized effects of manipulation on OM are unknown. Interference from swollen lymphatic tissues and/or muscle spasm may mechanically distort the eustachian tube or distort the small nerve fibers and blood vessels which serve the middle ear. Manipulation may relax muscle spasm and allow normal lymph, nerve and blood to flow. Also, Froehle states "Eustachian tube function depends upon appropriate contraction of the tensor veli palatine muscle, which in turn depends upon proper function of the mandibular branch of cranial nerve V, which in turn is dependent upon proper alignment and movement of the occiput and upper cervical vertebrae as

the nucleus of the spinal trigeminal tract extends down to the level of the upper cervical segments".<sup>17</sup> These mechanisms suggest a mechanical and nerve dysfunction as a potential cause of OM for which manipulative therapy may be beneficial. Therefore, this case report has potentially two different mechanisms of success: establishing the cranial nerve V flow at the level of the upper cervical vertebra and improvement of the child's lymphatic drainage. The possibility of spontaneous remission of OM cannot be ruled out.

The likelihood of spontaneous remission of conductive hearing loss in a case like this one is small. This is implied by a controlled trial of ear tubes (grommets), involving 55 children between 4 and 10 years of age, which found that within 6 months after insertion, the grommet ear and the control ear had the same average degree of hearing loss: 16 decibels. This hearing loss persisted for the entire five-year period of the study.<sup>33</sup> This suggests that complete spontaneous resolution of hearing loss over a period of eighteen months is unlikely.

While this represents only a single case, the suggestion it brings of normalization of auditory physiology by chiropractic manipulation is tantalizing. Additionally, it may represent a new method for monitoring the results of CMT in children with MEE or recurrent OME. A 1999 feasibility pilot study for clinical trials has suggested that performing

consistent tympanometry and/or pneumatic otoscopy in the chiropractic clinic setting may be impractical.<sup>34</sup> Most young children are uncooperative with repeated pneumatic otoscopy examinations. Attempting such examinations makes the performance of spinal manipulation more difficult due to vocalization and active resistance on the part of the patient. The availability of independent, non-medical practitioners in the audiology profession may present an opportunity to obtain reliable, objective criteria, on a pre- and post-treatment basis, for treatment effectiveness. An added advantage to this method would be that the patients would not come to associate the setting of the chiropractic clinic with an aversive stimulus (i.e.: an uncomfortable examination procedure). The major limitation of this measurement technique is that the minimum age for an accurate audiogram is approximately 5 years, so such studies of younger children would not be feasible

**Conclusion**

Conservative therapy such as chiropractic care with referral for audiology monitoring may offer children with otitis media and hearing loss a possible benefit of recovery from their condition without the concern of antibiotic side effects, antibiotic resistance, or risks of surgery and associated anesthesia.

**Consent**

Written informed consent was obtained from the patient for publication of this Case report and any accompanying images.

**References**

1. Laufer AS, Metlay JP, Gent JF et al. Microbial communities of the upper respiratory tract and otitis media in children. *MBio* 2011;2(1):e00245-10.
2. Zemek R, Szyszkowicz M, Rowe BH. Air pollution and emergency department visits for otitis media: a case-crossover study in Edmonton, Canada. *Environ Health Perspect* 2010;118(11):1631-1636.
3. O'Brien MA, Prosser LA, Paradise JL et al. New vaccines against otitis media: projected benefits and cost-effectiveness. *Pediatrics* 2009;123(6):1452-1463.
4. Wolleswinkel-van den Bosch JH, Stolk EA, Francois M et al. The health care burden and societal impact of acute otitis media in seven European countries: results of an Internet survey. *Vaccine* 2010;28 Suppl 6:G39-G52.
5. O'Reilly RC, He Z, Bloedon E et al. The role of extraesophageal reflux in otitis media in infants and children. *Laryngoscope* 2008;118(7 Part 2 Suppl 116):1-9.
6. Miyashita C, Sasaki S, Saijo Y et al. Effects of prenatal exposure to dioxin-like compounds on allergies and infections during infancy. *Environ Res* 2011;111(4):551-558.

7. Bentsdal YE, Haberg SE, Karevold G et al. Birth characteristics and acute otitis media in early life. *Int J Pediatr Otorhinolaryngol* 2010;74(2):168-172.
8. Post JC. Genetics of otitis media. *Adv Otorhinolaryngol* 2011;70:135-140.
9. Nelson HM, Daly KA, Davey CS et al. Otitis media and associations with overweight status in toddlers. *Physiol Behav* 2011;102(5):511-517.
10. Bonadio WA. The evaluation and management of acute otitis media in children. *Am J Emerg Med* 1994;12(2):193-206.
11. Daly KA, Hunter LL, Giebink GS. Chronic otitis media with effusion. *Pediatr Rev* 1999;20(3):85-93.
12. Kaleida PH; Rireman P. Diagnostic assessment of otitis media. *Clinical Allergy and Immunology* 2000; 15:260.
13. Williamson I. Otitis media with effusion in children. *Clin Evid* (Online) 2011;2011.
14. Carlin S, Marchant D, Shurin P, et al: Host factors and early therapeutic response in acute otitis media: Does symptomatic response correlate with bacterial outcome? *J Pediatr* 1991, 118; 178-183.
15. Hoberman A, Paradise JL, Rockette HE et al. Treatment of acute otitis media in children under 2 years of age. *N Engl J Med* 2011;364(2):105-115.
16. Bliner L, Devereaux T. Watchful waiting. A viable approach to acute otitis media. *Adv Nurse Pract* 2009;17(10):39-40.
17. Froehle RM. Ear infection: a retrospective study examining improvement from chiropractic care and analyzing for influencing factors. *J Manipulative Physiol Ther* 1996;19(3):169-177.
18. Degenhardt BF, Kuchera ML. Osteopathic evaluation and manipulative treatment in reducing the morbidity of otitis media: a pilot study. *J Am Osteopath Assoc* 2006;106(6):327-334.
19. Gouma P, Mallis A, Daniilidis V et al. Behavioral trends in young children with conductive hearing loss: a case-control study. *Eur Arch Otorhinolaryngol* 2011;268(1):63-66.
20. Dawes PJ, Welch D. Childhood hearing and its relationship with tinnitus at thirty-two years of age. *Ann Otol Rhinol Laryngol* 2010;119(10):672-676.
21. Browning GG, Rovers MM, Williamson I et al. Grommets (ventilation tubes) for hearing loss associated with otitis media with effusion in children. *Cochrane Database Syst Rev* 2010;(10):CD001801.
22. Teele D, Klein J, Pelton S, et al: Effects of persistent middle ear effusion on development of speech and language. *Pediatr Res* 1981; 68:869.
23. Ben-David J; Pdoshin L; Fradis M, Tympanometry and audiometry in diagnosis of middle-ear effusion. *Ear Nose Throat J* 1981 Mar; 60(3): 120-123.
24. Eliachar I; Jachims HSZ; Goldsher M; et al, Assessment of long-term middle ear ventilation. *Acta Otolaryngo* 1983 Jul-Aug; 96 (1-2): 105-12.
25. Harbert F; Young IM; Menduke H, Audiologic findings in serous otitis media. *Eye Ear Nose Throat Mon* 1970 Sep; 49(9): 409-11.
26. McCoul ED, Goldstein NA, Koliskor B et al. A prospective study of the effect of gastroesophageal reflux disease treatment on children with otitis media. *Arch Otolaryngol Head Neck Surg* 2011;137(1):35-41.

27. Abba K, Gulani A, Sachdev HS. Zinc supplements for preventing otitis media. *Cochrane Database Syst Rev* 2010;(2):CD006639.
28. Bronfort G, Haas M, Evans R et al. Effectiveness of manual therapies: the UK evidence report. *Chiropr Osteopat* 2010;18:3.
29. Ferrance RJ, Miller J. Chiropractic diagnosis and management of non-musculoskeletal conditions in children and adolescents. *Chiropr Osteopat* 2010;18:14.
30. Hawk C, Khorsan R, Lisi AJ et al. Chiropractic care for nonmusculoskeletal conditions: a systematic review with implications for whole systems research. *J Altern Complement Med* 2007;13(5):491-512.
31. Pilsner R, Richardson M. Improvements in hearing, speech, development and behavior following chiropractic in a 4 year old male. *Journal of Pediatric, Maternal and Family Health Chiropractic* 2011;2011(1):14-22.
32. Brown CDB. Improved hearing and resolution of otitis media with effusion following chiropractic care to reduce vertebral subluxation. *Journal of Pediatric, Maternal and Family Health Chiropractic* 2009;2009(1):1-7).
33. Brown MJ, Richards SH, Ambegaokar AG. Grommets and glue ear: a five-year follow up of a controlled trial. *J R Soc Med* 1978;71(5):353-356.
34. Sawyer CE, Evans RL, Boline PD et al. A feasibility study of chiropractic spinal manipulation versus sham spinal manipulation for chronic otitis media with effusion in children. *J Manipulative Physiol Ther* 1999;22(5):292-298.





# Chiropractic Care for Postpartum Pelvic Girdle Pain and Low Back Pain: A Case Report

Karen Gregory, BAppSc(Chiro) and Robert Rowell, DC, MS

## ABSTRACT

**Background:** It has been documented that between 50% to 80% of pregnant women suffer from low back pain. While pregnancy related pelvic girdle pain may be considered a “normal” part of pregnancy, it does not mean that there are no options for the patient both during and after pregnancy to help alleviate any discomfort.

**Objective:** This case describes the chiropractic care of a postpartum woman with pelvic girdle / low back pain.

**Clinical Features:** A 33-year-old, 3-month postpartum female presented for chiropractic care to help resolve her pelvic girdle / low back pain which she had suffered from since the birth of her daughter. She experienced pain in the left hip daily which was aggravated by bathing and lifting her daughter.

**Intervention:** A thorough physical and neurological examination was performed. Chiropractic adjustments consisting of Thompson, Activator, and Diversified techniques along with myofascial release of both round ligaments were given.

**Outcome:** Complete resolution of her pelvic girdle/low back pain.

**Conclusion:** There have been many risk factors documented for the cause of pregnancy related pelvic girdle or low back pain, and a number of quality of life consequences as a result. This paper illustrates the case of a patient who experienced resolution of her discomfort while under chiropractic care.

**Key words:** chiropractic, postpartum, pregnancy related, low back pain, pelvic girdle pain

## Introduction

Between 50% to 80% of pregnant women suffer from low back pain (LBP).<sup>1</sup> While back/pelvic girdle pain is often considered to be a normal consequence of pregnancy, it can have a significant impact on the quality of life of the patient as it can “disturb sleep, prevent women from going to work and interfere with ordinary daily activities such as carrying, cleaning, even sitting and walking.”<sup>2</sup>

A study conducted by Stepleton et al reported that over two-thirds (68%) of the subjects they reviewed continued to experience recurrent LBP after completing their pregnancies.<sup>3</sup> To and Wong reported that the “incidence of persistent back pain symptoms after pregnancy varied, from the disappearance of pain within 2 days of delivery for over 60%, to as high as 82% experiencing persistent pain at 18 months and that there was an overall incidence of around 21% still with pain at 2 years after delivery.”<sup>4</sup> Ostgaard et al noted that postpartum pregnancy related pelvic girdle pain (PPP) spontaneously disappeared within 3 months

in 93% of cases, and that 7% who do not recover have a greater risk of prolonged serious pain.<sup>5</sup>

A study by Albert et al found that 6 months after delivery all the women with symphyseal pain were better, and that 2 years after giving birth 4.2% and 6.5% of women who had experienced unilateral and bilateral sacro-iliac pain respectively continued to have pain, while 18% of the women who suffered from anterior and posterior pelvic pain were still having pain.<sup>6</sup>

Bastianseen et al, state that “pregnancy-related pelvic girdle pain (PPGP) is a complex phenomenon, and that previous studies could not convincingly distinguish low back pain from PPGP” therefore suggesting that pregnancy-related “back pain” form a specific syndrome.<sup>7</sup>

According to the European guidelines for the diagnosis and treatment of pelvic girdle pain, PGP is defined as “pain experienced between the posterior iliac crest and the gluteal fold, particularly within the vicinity of the SI joints,” while low back pain is “defined as pain between the 12th rib and the gluteal fold,”<sup>8</sup> and that PGP is diagnosed once lumbar causes are excluded. These guidelines concluded that PGP is a “specific form of low back pain (LBP) that can occur separately or in conjunction with LBP.”<sup>8</sup> The European guidelines also noted that PGP most commonly arises from pregnancy, trauma, arthritis and/or osteoarthritis.

**Karen Gregory, BAppSc(Chiro)**

*Private practice, Blackburn, Victoria, Australia*

**Robert Rowell, DC, MS**

*Diagnosis and Radiology Department, Palmer College of Chiropractic, Davenport, Iowa, USA*

*Corresponding author: kazgregory@yahoo.com*

Regarding the diagnosis of PGP they recommend the use of pain provocation tests such as P4/thigh thrust, Patrick Fabere, Gaenslen's Test and modified Trendelenberg's test, and pain palpation tests using the long dorsal sacroiliac ligament and palpation of the symphysis. The functional test recommended is the active straight leg raise (ASLR).

A report published by Noren et al found that women with pelvic pain had "greater functional impairments than those with lumbar pain, and that women who had a combination of the types of pain were more severely disabled than either of the two groups alone".<sup>9</sup> The European Guidelines for the diagnosis and treatment of pelvic girdle pain, document that pain can radiate to the posterior thigh, and diminishes the patient's capacity for standing, walking and sitting.

There are numerous causes given for the increased incidence of back pain in pregnancy which can include: previous history of low back pain, heavy work, smoking, contraceptive pills, increased weight during pregnancy, pluripara, increased stress levels, maternal age when pregnant and hormonal changes, altered posture due to the increased lumbar lordosis required to balance the anterior weight of the womb, ligamentous laxity caused by the hormone relaxin produced by the corpus luteum, and fluid retention within the connective tissue.<sup>2,10</sup>

The review of 34 relevant studies conducted by Wu et al, Pregnancy related pelvic girdle pain (PPP), found that there was a total of 15 possible risk factors for PPP and of those 15 there was strong evidence pointing toward strenuous work, previous low back pain and previous PPP, while weak evidence was found for maternal height and weight, the use of oral contraceptives, smoking, epidural anaesthesia and prolonged second stage labour.<sup>10</sup>

While pregnancy related pelvic girdle pain may be a "normal" part of pregnancy, it does not mean that there are no options for the patient both during and after pregnancy to help alleviate any discomfort. According to Lisi, while this pain can be quite disabling, as few as 32% of women report their symptoms to their prenatal provider and of these providers, only 25% recommend treatment.<sup>11</sup> The South Australian population survey conducted by Stapleton et al found that 48.9% of the 397 women surveyed did not receive any treatment for their pregnancy related back pain. Of those who did receive treatment 35% were recommended bed rest, 27% used pain-killing medication, 21% used physiotherapy treatment, 11% used chiropractic treatment, while the remaining 6% stated using other means.<sup>3</sup>

Chiropractic is a natural modality of choice used by many women during and after pregnancy to assist them in the birth process and the recovery. Chiropractic care has shown to have improved outcomes in pregnancy related LBP.1 A review of the literature performed by Borggren concluded that chiropractic care during pregnancy may be a "safe and effective means of treating common musculoskeletal symptoms that patients may encounter,"<sup>12</sup> they also reported that studies have shown that "chiropractic manipulation may significantly decrease the incidence of "back labour"" and that, "women who seek chiropractic care throughout gestation have shorter labour times."<sup>12</sup>

The purpose of this paper is to present the case of a woman with postpartum PPP who experienced relief of symptoms with chiropractic care. The key words used for the search of supporting evidence for this paper include: chiropractic, postpartum, low back pain, pelvic girdle pain, pregnancy related.

### Clinical Presentation

A 33-year-old 3-months postpartum female complaining of left low back pain, just above her hip which she had suffered from since the delivery of her daughter sought chiropractic care. The patient experienced the pain daily and noted that it radiated down the leg to above the knee. The pain was not excruciating, but was "not right" and was exacerbated by lifting and bending (especially for baths). The pain was subjectively reported by the patient. There was no noted change in sensory or motor function.

In reviewing her history it was found that she had been hospitalized for 4 days during the pregnancy due to mid back pain that radiated to the ribs, but there had been no recurrence of this pain since giving birth. The patient did receive chiropractic care in another office during her pregnancy from 23 weeks yet she felt "very uncomfortable" during her whole pregnancy. The patient experienced a degree of stress throughout her pregnancy journey due to renovating and selling their home and changing jobs.

The patient noted that she had experienced a tobogganing accident in 2006 where she had a bad fall onto the buttock which resulted in back issues, but did not have any treatment or radiographs taken at this time.

The patient's labor went over 2 days and concluded in a natural birth of a healthy baby girl; however, the recovery was delayed as the patient was torn badly and she suffered from a uterine infection requiring antibiotics.

Physical examination findings demonstrated a high right iliac crest, increased lumbar lordosis and forward head carriage with her posture. Her thoracolumbar range of motion was decreased in flexion and left lateral flexion. All thoracolumbar motion caused tension in the right sacroiliac (SI) joint. Seated Kemp's test was positive for local pain in the right SI and L5 area when the patient was taken into right lateral flexion and extension. Nachlas test was negative, however local pain was noted in the L4/5 region with flexion of the right knee i.e. bringing the foot to the buttock. Fabere test was positive for local right SI pain and the patient was found to have a tight left psoas muscle group. Using Thompson leg length analysis it was found that she had a short right leg going long on flexion of the knees to 90 degrees indicating a positive Derefield and therefore a SI subluxation.

Palpatory examination found increased muscle tone and decreased spinal joint motion with mild edema in the areas of C1, C2, C4, T7-9, L1, L5, right ilium and coccyx. As the patient was still breastfeeding it was decided that radiographs would not be obtained.

### Interventions and Outcomes

The patient was adjusted using numerous techniques. The right ilium was adjusted using Thompson technique. The patient was prone on the table and the right posterior ilium was contacted by the practitioner using the right hypothenar eminence over the posterior superior iliac spine while the left hand supported the left ischium and three posterior to anterior with slight inferior to superior directional thrusts were applied. Thompson drop table technique was also used to adjust the L5 where the practitioner used a broad thumb contact over the right body of L5 and applied a medial to lateral posterior to anterior thrust three times. An Activator II instrument was used on the coccyx, placing it gently to the right lateral and inferior side of the coccyx and applying one impulse on a setting of two rings. Diversified manual technique was used to adjust T7-9, C1 and C4. For the adjustment of T7-9 the patient was initially seated and relaxed with the chin tucked in slightly while the practitioner contacted the T9 vertebrae with a loose fist contact and then instructed the patient to allow herself to be layed back on the table by the practitioner. The thrust is a body drop impulse along the facet joints of T8. C1 and C4 were adjusted, contacting the left and the right respectively, using the lateral index finger contact over the neural arches while the patient was relaxed and supine. A high-velocity, low-amplitude (HVLA) thrust was applied in a lateral to medial and posterior to anterior direction. Myofascial release was performed on both round ligaments

while the patient was relaxed in the supine position with her knees flexed to 45 degrees and feet resting flat on the table. The round ligaments were addressed individually with a broad 5-finger contact over the superior aspect of the ligament while a broad 5-finger contact was under the posterior flank, directly opposite to the superior hand, a gentle torque was then used while the posterior hand held the torque in the opposite direction until a release was felt between the 2 contact hands.

The patient returned for a follow-up visit three days later and noted that she had had complete resolution of her left low back pain within 24 hours after her adjustment. The resolution of her pain was a subjective finding by the patient, and not noted by questionnaire. The patient was then not able to return for a further follow up for 18 days and on this visit noted that the pain had returned. The pain decreased subjectively in intensity again immediately after an adjustment. After a total of five chiropractic adjustments within a 4 week period, her pain had resolved and has continued to be resolved the past 4 months. The patient has continued with fortnightly wellness chiropractic care over the past 4 months. During the course of chiropractic care, the patient did not receive any other form of treatment. As she was breastfeeding over the counter medications were only very occasionally used and this was limited to acetaminophen.

A physical reassessment was conducted one month after initially presenting and objectively the patient demonstrated significant change. Her posture was balanced, her thoracolumbar range of motion was full, however, extension did cause some discomfort in the right SI joint. Fabere, Nachlas and Seated Kemp's were negative and without local pain. Leg lengths were balanced and subluxations were found at C1, C5, T8, T12, T10, L5 and right Sacrum.

### Discussion

As can be seen from the patient's presentation, her symptomatology is mixed. The patient presented with left low back pain above the hip, yet during physical assessment it was noted that her right SI joint was the cause of her discomfort. This mixed presentation can be common in the pregnant and post-partum patient as described above.

As stated in The European Guidelines for the diagnosis and treatment of pelvic girdle pain, pain does not have to be local but can radiate to the posterior thigh, which can affect the patient's ability to easily conduct everyday activities such as walking, standing or even sitting. This patient noticed that the pain was starting to have an impact on

her quality of life as it was becoming painful to bathe and even lift her daughter.

This patient presented to the practice at 3-months post partum, this is the time frame specified by Ostgaard et al that PPP can spontaneously resolve. However, as stated previously, pain can persist for up to at least 2 years postpartum. This patient could have possibly had spontaneous resolution of her PPP if no treatment was sought, however when referring to the collection of data, she may still have experienced discomfort for a longer period of time. Also, given that the patient had the recurrence of her PPP 18 days after the initial chiropractic adjustment, this decreases the chance that her pain spontaneously resolved, but rather was a consequence of her chiropractic treatment.

The patient in this case did not have an occupation that involved strenuous work nor have a previous pregnancy. However, the patient had experienced previous low back pain which started five years earlier caused by a tobogganing accident where she landed badly on her buttock, putting her in a high risk category for experiencing PPP as described by Wu et al.

From a chiropractic point of view, during pregnancy the “entire pelvis is capable of substantial fluidity of movement due to hormonal changes that occur to allow the pelvis to open enough for the passage of the baby.”<sup>13</sup> Biomechanically, with an increase in the lumbar lordosis to account for the increased weight anteriorly and the softening of the ligamentous and connective tissue, a woman’s centre of gravity changes over the nine months of pregnancy. Because of these postural changes and the softening of the ligamentous and connective tissue around the sacroiliac joints, pelvis, pubic symphysis and spine, pregnant women are predisposed to strains in supporting structures.<sup>14</sup> These changes can be a cause of vertebral subluxation and myofascial system tension and pain. Myofascial release of the round ligaments of the uterus may help to decrease the overall myofascial tension in the pelvis complementing the adjustive care the patient received.

The Vertebral Subluxation Complex, as defined by the Association of Chiropractic Colleges (ACC), is a “complex of functional and/or structural and/or pathological articular changes that compromise neural integrity and may influence organ system function and general health.”<sup>15</sup> Subluxation involving the lumbar plexus can result in “irritability and pain into the buttocks and down the leg.”<sup>13</sup> This case may demonstrate the sort of changes described in the ACC definition of subluxation.

## Limitations

During the assessment of this patient the chiropractor used the recommended diagnostic tests of Patrick Fabere, passive and active straight leg raises, while other SI/low back tests (Nachlas and Seated Kemp's) were also used. Pain and disability questionnaires are documented throughout the literature as a method of testing and assessing a patient's subjective level of pain. Ronchetti et al, use the Quebec Back Pain Disability Scale as one of the methods to help determine the severity of pelvic girdle pain.<sup>16</sup> A pain and disability or quality of life questionnaire was not used as a means of assessing the severity of the condition in this case therefore only the patient's subjective complaints are reported. This is a limitation of this case report. Future research should use objective measures to attempt to quantify patient improvement.

## Conclusion

While it is considered to be a “normal” consequence of pregnancy, many women experience and suffer from pelvic girdle or low back pain both during and after pregnancy. There have been many risk factors documented for the cause of pregnancy related pelvic girdle or low back pain, and a number of quality of life consequences as a result of this PPP. Numerous treatment suggestions have been described to help provide pregnant women with options and this paper illustrates the case of a patient who experienced resolution of her discomfort while under chiropractic care. Currently there is a lack of literature on the effects of chiropractic care on PPP. This paper illustrates a positive outcome for a patient with PPP. Although more research is needed, chiropractic care should be considered for pregnant women with PPP.

## References

1. Stuber KJ, Smith DL. Chiropractic Treatment of Pregnancy-Related Low Back Pain: A Systematic Review of the Evidence. *J Manipulative Physiol Thera* 2008; 31(6):447-454.
2. Young G, Jewell D. Interventions for preventing and treating pelvic and back pain in pregnancy. *Cochrane Database of Systematic Reviews*, 2002 Issue 1. Art. No.: CD00139. DOI: 10.1002/14651858.CD001139.
3. Stepleton DB, MacLennan AH, Kristiansson P. The prevalence of recalled low back pain during and after pregnancy: a South Australian population survey. *Australian and New Zealand J Obstetrics and Gynecol* 2002; 43:482-485.
4. To WWK, Wong MWN. Persistence of back pain symptoms after pregnancy and bone mineral density changes as measured by quantitative ultrasound — A two year longitudinal follow up study. *BMC Musculoskeletal Disorders* 2011,12:55.
5. Ostgaard HC, Andersson GB, Wennergren M. The impact of low

- back and pelvic pain in pregnancy on the pregnancy outcome. *Acta Obstetric and Gynecol Scandinavia* 1991; 70:21-24.
6. Albert H, Godskesen M, Westergaard J. Prognosis in four syndromes of pregnancy-related pelvic pain. *Acta Obstetrica et Gynecol Scandinavia* 2001; 80:505-10.
  7. Bastiaanssen JM, de Bie RA, Bastiaenen CHG, Essed GGM, de Brandt PA. A historical perspective on pregnancy-related low back and/or pelvic girdle pain. *European J Obstetrics and Gynecol and Reprod Biology* 2005; (120):3-15.
  8. Vleeming A, Albert HB, Ostgaard HC, Sturesson B, Stuge B. European Guidelines for the diagnosis and treatment of pelvic girdle pain. *European Spine J* 2008, (17):794-819.
  9. Noren L, Ostgaard S, Johansson G, Ostgaard HC. Lumbar back and posterior pelvic pain during pregnancy: A 3-year follow-up. *European Spine J* 2002; 11(3): 267-271.
  10. Wu WH, Meijer OG, Uegaki K, Mens JMA, van Dieen JH, Wuisman PIJM, Ostgaard HC. Pregnancy-related pelvic girdle pain (PPP), I: Terminology, clinical presentation and prevalence. *European Spine J* 2004; 13: 575-589.
  11. Lisi AJ, Chiropractic spinal manipulation for low back pain of pregnancy: a retrospective case series. *J Midwifery and Women's Health* 2006; Jan-Feb;51(1):e7-10.
  12. Borggren CL, Pregnancy and chiropractic: a narrative review of the literature. *J Chiropractic Med* 2007; (6): 70-74.
  13. Fallon J. Chiropractic & Pregnancy. Virginia: International Chiropractors Association; 1994.
  14. Levangie PK, Norkin CC. Joint Structure and Function: A Comprehensive Analysis. Sydney: MacLennan and Petty; 2001.
  15. Association of Chiropractic Colleges: Issues in Chiropractic. Position Statement #1. The ACC Chiropractic Paradigm, Chicago: Association of Chiropractic Colleges; 1996.
  16. Ronchetti I, Vleeming A, van Wingerden JP. Physical Characteristics of women with severe pelvic girdle pain after pregnancy: A descriptive cohort study. *Spine* 2008; 33(5):E145-51.



# Joint Hypermobility Syndrome: Which Intervention?

Joyce E. Miller, BSc, DC, DABCO, FCC and Sally L. Mathews, BSc(Hons)

## ABSTRACT

**Objective:** Adolescent back pain is becoming increasingly prevalent with levels approaching those of adults by late teens. Joint hypermobility syndrome (JHS) is a common cause of musculoskeletal symptoms in childhood, including back pain. These two facts combined suggest that the pediatric patient with JHS is likely to be a common presentation to the chiropractor's clinic. Failure to identify the condition could result in inappropriate care. This case report presents an appropriate management plan for hypermobile adolescents with back pain.

**Clinical Features:** A 15-year-old school girl with a history of childhood scoliosis and a year-long history of anterior rib pain presented to our clinic complaining of low back pain radiating to the lower ribs following an awkward movement 9 days earlier.

**Intervention and Outcome:** The patient was treated with gentle mobilization therapy and post-isometric relaxation to the quadratus lumborum, the external obliques, and the upper trapezius alongside daily proprioceptive exercises and early-stage core isometric strengthening exercises within neutral posture. Overall there was a reduction in pain from 8/10 to 4/10 as of treatment number 5 accompanied by a 28 point reduction on the Bournemouth Questionnaire.

**Conclusions:** This case report showed the possible beneficial effects of a multimodal treatment approach combining chiropractic treatment with proprioceptive exercises in a patient with generalized joint hypermobility syndrome.

**Keywords:** Adolescent, back pain, joint hypermobility syndrome, proprioceptive exercise

## Introduction

Joint hypermobility syndrome (JHS) is a hereditary connective tissue disorder characterized by lax joints and the presence of musculoskeletal symptoms. The syndrome has been under-recognized and has only recently started to be taken more seriously.<sup>1,2</sup> Prevalence in children has been estimated at 10-25%.<sup>1,2</sup> Females tend to be affected more than males, and those of African or Asian descent appear to be affected more than Caucasians. JHS may underlie common orthopedic problems such as back pain. Indeed, adolescent back pain is becoming increasingly prevalent as levels approach those of adults by late teens.<sup>3</sup> JHS has been cited as one of the most common differential diagnoses for back pain in children<sup>4</sup> and is a common reason for presentation to a rheumatologist in adults.<sup>2</sup> Back pain during adolescence can have profound effects on schooling and social relationships, with potentially serious repercussions should it lead to lengthy absences from school. This is a case of pediatric back pain complicated by JHS.

Certain sequelae of JHS are common. These include acute ligament and soft tissue injury, overuse injuries, pos-

sible increases in fractures and a possible predisposition to degenerative joint disease after years of excessive joint motion.<sup>5</sup> Left untreated or undiagnosed, hypermobility may result in a chronic pain cycle and high levels of disability.<sup>4</sup> Further, it has been shown that there is increased pain sensitivity in teenagers who have had early pain experiences.<sup>6</sup>

There is some disagreement as to the definition of JHS and a number of scales have been used to aid diagnosis. Traditionally, the Beighton Score<sup>7</sup> (*Table 1*) has been used to detect hypermobility. However, its clinical usefulness is sometimes questioned, primarily due to its focus on the upper body, which causes less disability than the lower limb, and the fact that, in the younger population, it has been suggested to over report hypermobility.<sup>4</sup>

A simple five-part questionnaire was devised by Hakim and Grahame<sup>8</sup> in 2003 (*Table 2*) and has a sensitivity of 85% and a specificity of 90% for detecting hypermobility should patients answer yes to two or more of the questions. A further refinement has been developed in the form of the Brighton Criteria (*Table 3*)<sup>9</sup> which also account for patient symptoms and are therefore useful in a clinical setting.

## Case report

A 15-year-old girl of Asian descent presented with low back pain of 9 days duration with radiation anteriorly

---

Joyce E. Miller, BSc, DC, DABCO, FCC  
Anglo European College of Chiropractic,  
Bournemouth, Dorset, UK  
Email: jmiller@aecc.ac.uk

**The Beighton score for assessing hypermobility<sup>6</sup>**

Numerical score of 0-9 generated via the following:

- **One point for ability to perform each of the following tests:**
  - Passive dorsiflexion of the little fingers beyond 90°
  - Passive apposition of the thumbs to the flexor aspects of the forearms
  - Hyperextension of the elbows beyond 10°
  - Hyperextension of the knees beyond 10°
  - Forward flexion of the trunk, with knees straight, so that the palms of the hands rested easily on the floor
- **One point for each affirmative answer to the following questions:**
  - Any pains in the hands or feet?
  - Any other joint pains?
  - Any backache?
  - Any other pains in the limbs?

**Table 1.**

to the lower ribs. The problem had begun when awkwardly alighting from her bed. She described the pain as a dull tightness, escalating to shooting sharp pains on certain movements which she rated 8/10 in intensity. She consulted her general practitioner the following day and was prescribed co-codamol analgesia which was mildly relieving. She also noted a year long history of anterior rib pain on the left after walking long distances or carrying her school bag and discomfort in the upper back related to sitting and studying. She had already missed 2 weeks of school due to pain since the start of the year 9 weeks ago, leading her mother to seek alternative care. At age 3 she was diagnosed with a scoliosis, which had self-resolved by the age of 10. She has always considered herself ‘double jointed’ and noted that her brother was too. She was able to answer yes to 3 of the 5 questions in the Hakim and Grahame<sup>7</sup> questionnaire for the detection of hypermobility (Table 2).

Physical examination confirmed the presence of joint laxity and showed bilateral pes planus. The quadratus lumborum and external obliques were tender to palpation bilaterally. There were a number of tender and restricted

areas in the thoracic spine, but no neurological signs were present. JHS is a diagnosis of exclusion with rule-outs of Erlos Danlos syndrome, Marfan syndrome and juvenile idiopathic arthritis.

The diagnosis of JHS leads to questions about appropriate treatment options for this child’s back pain. The presence of generalized joint laxity brings into question whether high velocity manual thrust techniques are appropriate. A search of the scientific literature over the past ten years was conducted to investigate the best evidence for appropriate care and its effectiveness in similar cases. The original paper outlining the Beighton Score<sup>6</sup> was included, despite falling outside the primary search time frame, for completeness.

**Discussion**

There is no evidence specific to chiropractic care and the pediatric population with JHS. However there is some level 4 evidence (case report and case series)<sup>10,11</sup> investigating the use of manual therapy alongside functional rehabilitation training in this group. Table 4 shows the results of a large case series of individuals treated with a three week exercise programme where 69% of participants showed improvement at six week review. There was a significant positive relationship between age and outcome. This may be explained by other factors, such as onset of puberty, natural stiffening up over time or greater compliance in older children.

Such minimal evidence as there is suggests that manual therapy alongside functional rehabilitation training — with an emphasis on improved motor control, proprioception and strength-endurance<sup>10,11</sup> may lead to long term

**5 point hypermobility questionnaire<sup>7</sup>**

- Can you now [or could you ever] place your hands flat on the floor without bending your knees?
- Can you now [or could you ever] bend your thumb to touch your forearm?
- As a child, did you amuse your friends by contorting your body into strange shapes or could you do the splits?
- As a child or teenager, did your kneecap or shoulder dislocate on more than one occasion?
- Do you consider yourself “double-jointed”?

**Table 2.**

**Brighton criteria for joint hypermobility syndrome**

(after Grahame *se al.*, 2000 in Simmonds and Keer<sup>8</sup>)

**Major criteria**

- A Beighton score of 4/9 or greater (either currently or historically)
- Arthralgia for longer than 3 months in four or more joints

**Minor criteria**

- A Beighton score of 1, 2 or 3/9 (0,1,2 or 3 if aged 50+)
- Arthralgia (for 3 months or longer) in one to 3 joints or back pain (for 3 months or longer), spondylosis, spondylolysis or spondylolisthesis
- Dislocation/subluxation in more than one joint, or in one joint on more than one occasion
- Soft tissue rheumatism: three or more lesions (e.g. epicondylitis, tenosynovitis, bursitis)
- Marfanoid habitus (tall, slim, span/height ratio > 1.03, upper:lower segment ratio < 0.89, arachnodactyly (positive Steinberg/wrist signs)
- Abnormal skin striae, hyperextensibility, thin skin, papyraceous scarring
- Eye signs: drooping eyelids or myopia or anti-mongoloid slant
- Varicose veins or hernia or uterine/rectal prolapse

Joint hypermobility is diagnosed in the presence of two major criteria or one major and two minor criteria, or four minor criteria. Two minor criteria will suffice where there is an unequivocally affected first-degree relative.

**Table 3.**

amelioration of low back pain in hypermobile patients. Treatments focus on improving muscle control in the presence of ligamentous insufficiency to help to minimize trauma to joints. It is commonly recognised that children respond well to muscle-strengthening exercises — although muscle bulk may not increase as improvement in strength and neuromuscular co-ordination results in more efficient muscle use.<sup>4</sup>

It is interesting to note that our patient was very active, swimming competitively until a year ago when she decided to focus on her studies. The cessation of activity coincides with the onset of back and rib pain. Modification of activities, alongside rehabilitation exercises are

suggested from the literature to be the key to improved outcomes in the presence of JHS.<sup>10,11</sup> The patient was instructed in daily proprioceptive exercises and early-stage core isometric strengthening exercises within neutral posture. She was treated with gentle myofascial therapy and post-isometric relaxation to the quadratus lumborum, the external obliques and the upper trapezius.

The patient rated her pain as 8 on the Numerical Rating Scale (NRS) which spans 0 to 10, where 0 is no pain and 10 is the most or worst pain. Although the NRS has been studied extensively in adults and has good evidence of acceptability, reliability and validity, there is little data to support the use of the NRS in the pediatric population. However, there is some indication that the scale is useful for children 8 years and older.<sup>12</sup> The patient's self-reported pain was reduced from 8/10 to 6/10 as of treatment number 5.

The NRS value remained relatively high. It has been shown that pain is often the last thing to improve in the presence of continuing joint laxity and when it does, it only does so slowly. This is an important point to emphasize at the start of treatment.<sup>4</sup> The clinical course of patients with JHS may be one of ups and downs as patients are subject to recurrent soft tissue injury, a further point of note when discussing treatment options with patients.<sup>4</sup>

**Conclusion**

JHS is a common cause of musculoskeletal symptoms

**Results of a case series where JHS was treated with a 3 week exercise program<sup>9</sup>**

- 39 participants, 2-14 years of age
- Diagnosis of JHS using the Beighton Score<sup>6</sup>
- 3 week exercise program with 6-week follow-up
- 69% were improved at 6-week review (using global scale of patient-reported symptomatic relief)
- 15% had complete resolution of symptoms
- The older the child the lower the Beighton Score<sup>6</sup> at onset of symptoms (significant negative relationship between the two (R = -0.53; P <0.01))
- Significant positive relationship between age and outcome (R = 0.4; P <0.01)

**Table 4.**



**Case study of a 16-year-old male student with JHS and chronic back pain<sup>10</sup>**

- 16-year-old male high school student with chronic low back pain
- Diagnosis of joint hypermobility syndrome and Marfanoid habitus
- Treatment with postural education, lumbar control exercises, gentle mobilisation of upper lumbar and lower thoracic segments, soft tissue release of lumbar and thoracic paraspinal muscles, proprioception and strength endurance
- 17-week program
- Patient self-assessment reported 90-95% improvement, almost complete resolution of back pain and improved spinal and lower limb movement control

**Table 5.**

in childhood<sup>4</sup> and should be born in mind for all pediatric patients as ligament laxity may be the rule rather than the exception. The condition should be diagnosed prior to commencement of treatment and the goal of therapy should be stabilization of lax joints rather than manipulation, which may result in destabilization.

This case report illustrates a relatively common presentation of adolescent low back pain. The case emphasizes the importance of early recognition of JHS and its impact on patient management, as it needs to be long-term. A multimodal treatment approach combining myofascial therapy with proprioceptive exercises is important in amelioration of long term pain.



**References**

1. Grahame R. Joint hypermobility and genetic collagen disorders: are they related? *Arch Dis Child* 1999; 80:188-91.
2. Grahame R and Hakim A. High prevalence of joint hypermobility syndrome in clinic referrals to a north London community hospital. *Rheumatology* 2004;43(2):ii91.
3. Davies K and Copeman A. The spectrum of paediatric and adolescent rheumatology. *Best Pract Res Clin Rheumatol* 2006; 20(2):179-200.
4. Murray KJ. Hypermobility disorders in children and adolescents. *Best Pract Res Clin Rheumatol* 2006; 20(2):329-51.
5. Simpson MR. Benign joint hypermobility syndrome: evaluation, diagnosis and management. *JAOA* 2006; 106: 531-36.
6. Hermann C, Hohmeister J, Demirakca S, Zohsel K and Flor H. Long-term alteration of pain sensitivity in school-aged children with early pain experiences. *Pain* 2006; 125: 278-285.
7. Beighton P, Solomon L and Soksolne CL. Articular mobility in an African population. *Ann Rheum Dis* 1973; 32:413-18.
8. Hakim A and Grahame R. A simple questionnaire to detect hypermobility: an adjunct to the assessment of patients with diffuse musculoskeletal pain. *Int J Clin Pract* 2003; 57(3):163-66.
9. Simmonds JV and Keer RJ. Hypermobility and the hypermobility syndrome. *Manual Ther* 2007;12:298-309.
10. Kerr A, Macmillan CE, Uttley WS and Luqmani RA. Physiotherapy for children with hypermobility syndrome. *Physt* 2000;86(6):313-17.
11. Simmonds JV and Keer RJ. Hypermobility and the hypermobility syndrome, Part 2: Assessment and management of hypermobility syndrome: Illustrated via case studies. *Man Ther* 2008;13:e1-11.
12. von Baeyer CL, Spagrud LJ, McCormick JC, Choo E, Neville K and Connelly MA. Three new datasets supporting use of the Numerical Rating Scale (NRS-11) for children's self-reports of pain intensity. *Pain* 2009;doi:10.1016/j.pain.2009.03.002.
13. Post-treatment Bournemouth Questionnaire reproduced with kind permission from the AECC, [http://www.aecc.ac.uk/research/bmth\\_questionnaire/index.asp](http://www.aecc.ac.uk/research/bmth_questionnaire/index.asp)

# Benefits of Chiropractic Care on an Infant Demonstrating Congenital Myogenic Ptosis: A Case Study

Jennifer T. Murphy, DC, DICCP and Casey Crisp, DC, MS

## ABSTRACT

**Objective:** The purpose of this case report is to describe the clinical presentation and chiropractic management of an infant with congenital myogenic ptosis of the eye.

**Clinical Features:** A one month old female with a history of congenital myogenic ptosis since birth.

**Intervention and Outcome:** Chiropractic treatment plan consisted of gentle upper cervical chiropractic adjustments and cranio-sacral therapy administered over an 8 week period. Partial improvement was seen in eye motion and blinking ability. In hopes of restoring complete motion, a referral for surgery was given. The surgical outcome was successful. This case report is designed to present (1) proper referral procedures and (2) to explore whether chiropractic care might benefit an infant prior to implementing surgical intervention or (3) as an adjunct to surgical procedures.

**Conclusion:** This case report suggests that chiropractic may provide a complement to traditional treatment options.

**Key Words:** chiropractic, ptosis, cranio-sacral technique, cranial nerve

## Introduction

Ptosis or blepharoptosis is defined as the drooping of a body part, in this case the eyelid, which “droops” or does not open. It is marked by an abnormally low-lying upper eyelid margin in primary gaze, resulting in narrowing of the palpebral opening.<sup>1</sup> Determination of “normal” eyelid opening is determined as the eyelid crease is only slightly less than 1/3 the distance from the lash line to the lower eyebrow. There is a slight variant in Asian and African children due to genetic physical characteristics.<sup>2</sup> However, there is no evidence of differences among races or genders in cases of blepharoptosis.

## Classifications of Ptosis

There are 6 forms of ptosis, classified based on onset, age of patient, severity (mild, moderate, severe), causation, and levator muscle function (poor, moderate, good). They are:

1. *Idiopathic ptosis* is of unknown etiology.
2. *Neurogenic ptosis* includes oculomotor nerve palsy, Horner's Syndrome, Marcus Gunn jaw winking syndrome, 3rd cranial nerve misdirection.

3. *Myogenic ptosis* is common with myasthenia gravis, myotonic dystrophy, ocular myopathy, blepharophthalmos syndrome, and simple congenital ptosis.
4. *Aponeurotic ptosis* may be post-operative or involuntary from CNS dysfunction. Mechanical ptosis occurs due to tumors of the eyelid, scarring or edema.
5. *Traumatic ptosis* results from birth trauma, contact lens injury, orbital fracture or brain injury.
6. *Neurotoxic ptosis* results from a venom reaction from cobras or kraits and Pseudo ptosis results from lack of lid support or a higher lid position from external measures.

In this report myogenic congenital ptosis is the primary diagnosis.<sup>2</sup>

Ptosis occurs when the Muller and levator muscles fail to open the eye properly. The etiology of congenital ptosis is generally unknown. Trauma to the 3rd cranial nerve or muscles of the eyelid in-utero or during the birth process, along with an underlying brain tumor, diabetes mellitus or other myasthenia conditions are rare.<sup>2</sup>

Ptosis can interfere with the sensory input of the affected eye on one or both sides, interfering with the development of an infant's vision and proprioception.<sup>3</sup> Moderate to severe congenital or acquired ptosis is typically treated with surgical intervention.<sup>2</sup> Knowledge of the cranial nerves which innervate the muscles of the eye, the optic nerve and the biomechanics of the frontal, temporal, ethmoid and sphenoid bones is necessary to both evalu-

---

**Jennifer T. Murphy, DC, DICCP**

Private practice, Pink Hill, North Carolina, USA

**Casey Crisp, DC, MS**

Palmer College of Chiropractic, Davenport, Iowa, USA

Corresponding author:

Dr. Jennifer Murphy. [kidsluvdrj@gmail.com](mailto:kidsluvdrj@gmail.com)

# of Visits	Physician	Physician Care Provided	Notes
1	1st Ophthalmologist	Evaluation	Wait and See
2	Chiropractor	Evaluation, Adjustment and CST	Noted facial asymmetry
3	Chiropractor	Adjustment and CST	Improvement in cranial motion
4	2nd Ophthalmologist	Evaluation	Surgery set
5	Chiropractor	Adjustment and CST	Little noted improvement
6	Chiropractor	Adjustment and CST	Eye began to open on own, face more symmetrical
7	Chiropractor	Adjustment and CST	More rotational ROM in cervical spine, eye opening more, infant rolling over
8	Chiropractor	Adjustment and CST	Sleep and eating patterns improving-referred to more local DC
9	2nd Ophthalmologist	Surgery	Positive outcome with eye now able to fully without outside manual stimulation. Pt observed every few weeks post surgery by Ophthalmologist

**Table 1. Patient visits for Ptosis**

ate and appropriately determine listings and chiropractic techniques to administer for the purpose of normalizing neural input for proper eye mechanics.<sup>4</sup> Adjustment of the upper cervical spine along with the bones of the cranium is hypothesized to allow injured nerves to regenerate resulting in restored movement.<sup>5</sup>

The majority of papers published on eyelid ptosis discuss surgical intervention or are directly related to a visceral disease process in which ptosis is a related symptom.<sup>6-8</sup> Surgical interventions include levator muscle resection, Muller muscle-conjunctival resection, frontalis suspension procedure, or Fasabekka-Servat procedure. Following surgery, patients are monitored every 2-4 weeks for correction issues, infection, granuloma formation or keratopathy.<sup>9</sup>

**Case Report**

A one-month-old female with a Caucasian father and Asian mother presented with a chief complaint of congenital ptosis of the left eye. The mother and hospital staff noted the left eye opened on the first day of life, but after that initial day, the eye required external force be applied to lift the lid. There was no record of trauma reported or an explanation given as to why the left eyelid no longer functioned properly. The right eye opened within normal parameters.

The patient’s history was fairly unremarkable. Maternal

history demonstrated an uncomplicated pregnancy, noting minimal morning sickness and a weight gain of 20 pounds. A “normal” vaginal delivery with no intervention was also noted in the record. Neonatal history included breastfeeding and steady weight gain with regular bowel movements. A familial history of a sibling with mild ptosis that did not require medical intervention was noted. There was no record of the ptosis 4 days post birth by the pediatrician although the patient’s mother noted her concern on the “Parent’s Page” (paperwork filed at the pediatrician’s office) on the day of the visit. The diagnosis of congenital ptosis was recorded by the pediatrician 20 days post birth. The pediatrician also recorded that he observed “symmetrical facies”, with the exception of the left eyelid ptosis, and a referral was made to an ophthalmologist. A diagnosis of severe ptosis affecting the left upper eyelid was confirmed by the ophthalmologist. The fundal examination was normal. It was recommended they return for reevaluation in 2 months.

The parents chose to pursue chiropractic care and the patient was seen in the author’s office on the following day.

Upon examination the infant was unable to open the left eyelid without assistance. When the eyelid was opened manually, the eye was unable to focus on any presented object and did not move towards external stimuli such as

the sound of a rattle or her mother's voice. Both blink and acoustic reflexes were absent. A left head tilt was noted along with an eccentric head shape, oblong with the mandible perpendicular to the right eye. The left parietal bone was ridged over the top of the temporal bone. All other exams had no significant findings.

Adjustments were performed on the right atlas which was fixed in rotation and adjusted posterior to anterior (P-A) contacting the posterior arch with a single digit contact and on the left axis which was fixed in rotation and adjusted posterior to anterior contacting the posterior arch with a single digit contact. Cranio-sacral technique (sphenofrontal release at the lesser wing)<sup>10</sup> was performed along with a parietal lift. A referral to a pediatric ophthalmologist was suggested to seek a second opinion.

The opinion of the second ophthalmologist was that surgical intervention was prudent. The parents consented to the procedure. The ophthalmologist performed a frontalis sling blepharoptosis repair with a Seiff silicone rod to the left upper eyelid. The surgeon considered the procedure successful and the patient was released to her original ophthalmologist for follow up as she was considered at risk for amblyopia which is a disorder of the visual system that is characterized by a vision deficiency in an eye that is otherwise physically normal.

## Discussion

In this case, the initial ophthalmologist chose a "wait and see" attitude regarding treatment for the ptosis. The chiropractic physician and second ophthalmologist concluded that complete loss of vision in one eye for an extended period of time had the potential for long term disability and recommended the surgery be performed as soon as possible. Loss of visual input has been very difficult to assess, but a study by Wiesel and Hubel on visual deprivation in kittens demonstrated that significant monocular or binocular deprivation leads to virtual blindness due to loss of neural connections between the eyes, optic nerves and cortical connections. Behavioral changes, including loss of self assurance and self esteem were noted, although some behavioral recovery did occur after the blindness was resolved.<sup>11</sup> Although unclear what duration of full visual deprivation would cause permanent damage in an infant, early intervention seemed most prudent to optimize the development of sight and the associated neural connections.

There is very little published research regarding chiropractic adjustments or other forms of spinal manipula-

tive therapy involving ptosis cases available, but a few have noted positive results.<sup>4,12</sup> A case report involving a two year old female with myasthenia gravis and lower extremity weakness resolved following 5 months of regular contact-specific, high-velocity, low-amplitude chiropractic adjustments in the upper cervical and sacral spine.<sup>2</sup> Physical therapist Damon Daura noted significant improvement in a 36 year old woman with cervical and upper thoracic pain and TMJ issues with the Maitland Assessment plan (which is a manual manipulative technique).<sup>12</sup> In each of these cases, chiropractic adjustments or other manual manipulative therapy stimulated a neurological response that altered the pattern of firing of the levator palpebrae superioris (LPS). The LPS originates at the inferior aspect of the lesser wing of the sphenoid bone and inserts into the superior tarsal plate and skin of the upper eyelid and is innervated by the superior division of the oculomotor nerve (Cranial Nerve III).<sup>13</sup>

Each of the above-cited studies stated that upper cervical adjustments influenced the LPS by working through the afferent receptors to the intermedius nucleus of the medulla.<sup>14</sup> The intermedius integrates information from the head and neck and relays the information to the nucleus of the solitary tract (Nucleus Tractus Solitarii or NTS) where autonomic responses are generated. Also, sensory nerves from the suboccipital muscles, the sternocleidomastoid muscle and the longus capitus muscle, each directly influenced by the cervical adjustment, project to the nucleus intermedius through the upper cervical dorsal root ganglion creating chemical and electrical stimulation releasing excitatory and inhibitory post-synaptic potentials in the solitary tract.<sup>14</sup> Trophic changes from interrupted sensory impressions are hypothesized to alter nerve repair. This theory could be applied to involvement of the levator palpebrae superioris muscle and its innervations from the oculomotor nerve. An irritation or stimulus to the oculomotor nerve would prevent the natural function of the LPS resulting in ptosis.<sup>15</sup>

Cranio-sacral therapy (CST) employs multiple techniques to influence the positioning and motion of the origin of the LPS.<sup>10</sup> The sphenoid is central to the functional mechanics of the cranium. Its close relationship to the third cranial nerve (CNIII) may explain a positive response when these techniques are employed to restore motion.<sup>10</sup> Thirteen bones articulate directly with the sphenoid. These include the occiput, temporal, parietals, ethmoid, palatines, frontal, and vomer. At the anterior pole, many of the cranial nerves pass through, under, or over it. Passing through the sphenoid and the cavernous sinus, Cranial Nerve III originates

from the diencephalon. This small section of the brain controls movement, especially those of the eye, but also filters or increases the amount of stimulation to the upper brain. To hold balance with the sphenoid, the sacral adjustment may be crucial as they are designed to be synchronized in rhythmic motion (craniosacral rhythm).<sup>10</sup>

This is the outcome of only one case report and should be compared with others before a conclusion can be drawn. However, it is the author's hope that it demonstrates not only a need for further study in this area and continued evaluation of opportunities for chiropractors to collaborate with other healthcare specialists.

An issue to be explored is whether ptosis should be viewed as a viscerosomatic or musculoskeletal condition. If the LPS is the primary cause of the condition, then it is a simple musculoskeletal case. However, if the trophic changes to the nerves or cranial nerve dysfunction is the underlying cause of the LPS, then a case for a visceral component which is now beginning to appear in the literature 16-19 should be investigated further.

This report also demonstrates the value of pursuing a second opinion from a different specialty to achieve a more expedient treatment care outcome. Contrary to Vohra's discussion that chiropractors lack knowledge of "serious childhood conditions" and might cause a delay in diagnosis of serious conditions, the exact opposite occurred with this patient.<sup>20</sup> The "wait and see" medical plan by the initial ophthalmologist would have delayed any type of proactive interventive care to the patient for an additional two months before another analysis would have been done. This could have resulted in visual impairment and/or neurological stagnation in the long term as well as a more difficult and less successful surgical outcome. The chiropractor in this case was concerned by the long term ramifications of delayed treatment and sought a second opinion from a different ophthalmologist. This led to immediate surgical intervention and a successful patient outcome. This coupled with an appropriate treatment plan to facilitate neurological function for the patient may be an illustration of optimizing outcomes through collaboration. More exploration into interdisciplinary cooperation for the benefit of the patient should be embraced.

### Conclusion

Chiropractic care has long been known as a pain relieving health care profession. Further investigation is needed into the possible connection between chiropractic adjustments and effects on non-musculoskeletal complaints

as well as the potential for interdisciplinary collaboration between chiropractors and other healthcare providers.

### References

1. Collin JRO. Ptosis. In: *Manual of Systematic Eyelid Surgery*. Oxford, England: Butterworth-Heinemann. 1999;41-72.
2. Finsterer J. Ptosis: causes, presentation and management. *Aesth Plast Surg* 2003; 27:192-204.
3. Chen H, Tourtellotte W, Frank E. Muscle spindle-derived neurotrophin 3 regulates synaptic connectivity between muscle sensory and motor neurons. *J Neuroscience* 2002; 22(9):3512-3519.
4. Alcantara J, Plaugher G, Araghi HJ. Chiropractic care of a pediatric patient with myasthenia gravis. *J Manipulative Physiol Ther* 2003 Jul-Aug;26(6):390-4.
5. American Chiropractic Association: Mission and Definition of Chiropractic. [www.acatoday.org](http://www.acatoday.org)
6. Baggio E, Ruban JM. Postoperative ptosis: Etiopathogenesis, clinical analysis and the therapeutic management. Apropos of a series of 43 cases. *J Fr Ophthalmol* 1998; 21:361-373.
7. Berry-Brincat A, Willshaw H. Paediatric blepharoptosis: a 10-year review. *Eye* 2009; 23(7):1554-9.
8. Bagheri A, Aletaha M, Saloor H, Yazdani S. A randomized clinical trial of two methods of fascia lata suspension in congenital ptosis. *Ophthalm Plast Reconstr Surg* 2007; 23(3):217-21.
9. Brodsky, MC. The doctor eye seeing through the myopathy of congenital ptosis. *Ophthalmology* 2000; 107(11):1973-1974.
10. Milne, H. *The Heart of Listening*. Berkeley, CA: North Atlantic Book, 1995.
11. Wiesel TN, Hubel DH.: Extent of recovery from the effects of visual deprivation in kittens. *J Neurophysiology* 1965; 28: 1060-1072. (<http://jn.physiology.org/cgi/reprint/28/6/1060>).
12. Daura, D. Case report: Maitland assessment and treatment of a patient with eye ptosis secondary to cervicall-thoracic dysfunction. Springfield, VA: First Annual Maitland Symposium, 2010.
13. Standring S. *Gray's Anatomy: the Anatomical Basis of Clinical Practice, 39th edition*. Secaucus, NJ: Elsevier limited 2005; 391.
14. Edwards I, Deuchars S, Deuchars J. The intermedius nucleus of the medulla: A potential site for the integration of cervical information and the generation of autonomic responses. *J Chem Neuroanatomy* 2009; 38(3)166-175.
15. Quinby W. The treatment of trophic nerve lesions: a study based on a case of mal perforans; of ischemic paralysis; and of erythroelalgia. *Boston Med Surg J* 1908;158:281-284.
16. Hawk C, Khorsan R, Lisi A, Ferrance RJ, Evans MW. Chiropractic care for non-musculoskeletal conditions: a systematic review with implications for whole systems research. *J Alternative Complementary Med* 2007; 13(5):491-512.
17. Nansel D, Szlazak M. Somatic dysfunction and the phenomenon of visceral diseases simulation: a probable explanation for the apparent effectiveness of somatic therapy in patients presumed to be suffering from true visceral disease. *J Manipulative Physiol*

*Ther* 1995 (Jul); 18 (6):379-397.

18. Plaugher G, Long C, Silveus A., Wood H, Lotun K, Menke M, Meeker W, Rowe S. Practice-based randomized controlled-comparison clinical trial of chiropractic adjustments and brief massage treatment at sites of subluxation in subjects with essential hypertension: pilot study. *J Manipulative Physiol Ther* 2002; 25(4):221-239.
19. Hubbard T, Crisp C. Cessation of cyclic vomiting in a 7-year-old girl after upper cervical chiropractic care: a case report. *J Chiropr Med* 2010; 9:179-183.
20. Vohra S, Bradley, J, Cramer K, Humphreys K. Adverse events associated With pediatric spinal manipulation: a systemic review. *Pediatrics* 2007 Jan; Vol. 119 No. 1 pp. e275 -e283. (doi: 10.1542/peds.2006-1392)



# Improvement of Chronic Constipation in a 5-Year-Old Female after Chiropractic Treatment

Carol Parnell, DC, DICCP and Amin Nekoomand, DC

## ABSTRACT

**Objective:** To discuss the chiropractic management of a pediatric patient who sought care for chronic constipation.

**Clinical Features:** 5-year-old female with chronic constipation since birth. Her symptoms included abdominal pain, gas, and abdominal bloating. Current treatment consisted of laxatives, high fluid intake, and high fiber intake which had not been effective.

**Intervention and Outcome:** The patient received full-spine diversified treatments over a period of 6 weeks. She was able to have a significant bowel movement a few hours after her first treatment. Her abdominal gas, bloating and pain were eliminated. Her bowel function continued to improve with further chiropractic treatments with sustained results.

**Conclusion:** This case suggests that chiropractic full spine diversified adjustments may be helpful in some cases of chronic constipation.

## Introduction

Constipation is a frequent and common occurrence in children, affecting 4%-30% of the population by various estimates, with 1 study of 482 children showing an incidence rate of 22.6%.<sup>1</sup> It accounts for 3% of visits to general pediatricians and nearly 30% of visits to pediatric gastroenterologists.<sup>2</sup> Causes are attributed to insufficient fluid intake, insufficient fiber intake, or a diet high in constipating foods i.e. milk, cheese, bananas. Allopathic treatment consists of stool softeners (laxatives) and having the child change to a less constipating diet with more fiber and fluids. Constipation is defined as "the slow movement of feces through the large intestine."<sup>3</sup> Signs and symptoms of constipation in children may include no bowel movements for several days; bowel movements that are hard, dry and difficult to pass; abdominal pain; nausea; and traces of liquid or clay-like stool in the child's underwear (a sign that stool is backed up in the rectum); bright red blood on the surface of hard stool; poor appetite; cranky behavior.

There are few reports of chiropractic treatment for chronic constipation in children in the literature. The first was reported by Hewitt in 1993 and involved the normalization of bowel function in a 7-month-old female after treatment with full spine and cranial adjusting.<sup>4</sup> Ericksen

reported significant improvement in bowel function in a 5-year-old girl with chronic constipation after Grostic upper cervical care.<sup>5</sup> In 1994, Marko reported treatment of a 10-month-old female, who developed constipation after being switched from an exclusively breast-fed diet to solid foods.<sup>6</sup> The patient was treated using the Chiropractic Biophysics Technique and demonstrated improvement in symptoms although still sometimes experienced difficult bowel movements. In 2008, Alcantara and Mayer described the successful outcome of chiropractic care in 3 pediatric patients with chronic constipation. All 3 patients were under 2 years of age and responded immediately with improved bowel function attributable to chiropractic care.<sup>7</sup>

In the present study, the case history, chiropractic management, and clinical outcomes in a 5-year-old female patient with chronic constipation are reported.

## Case Report

A 5-year-old female, accompanied by her mother, had a history of chronic constipation and related symptoms including distended abdomen, gas and pain. Her mother stated this had been a recurring problem since birth with the child averaging only one small, hard, painful bowel movement per week. Previous treatment consisting of laxatives, water and higher fiber diet had failed to help. The child was delivered by emergency C-section after 52 hours of labor in the hospital. She weighed 9 pounds, 10 ounces and was 20 inches in length. At birth her mother was told she had "low tone" and the child remained in the hospital for the first 7 days due to jaundice. She had constipation and gastric reflux since birth. She was prescribed Prevacid at birth for

**Carol Parnell, DC, DICCP**

*Private practice, Nashua, New Hampshire, USA*

**Amin Nekoomand, DC**

*Graduate Fellow, Palmer Center for Chiropractic Research, Davenport, Iowa, USA*

*Corresponding author: parnellchiro@comcast.net*

the reflux, which she took for the first year of her life. She was prescribed Miralax at 6 weeks for the constipation and continued to take it daily until beginning chiropractic care. The mother began breastfeeding at birth but was told she was not producing sufficient milk and the feedings were augmented after several days with a milk-based formula. For the next 6 weeks her feedings were split approximately equally between breastfeeding and milk-based formula. After 6 weeks she was diagnosed with a milk protein allergy and was fed a milk-free formula exclusively until she reached twelve months of age.

When first seen in the chiropractic office, the child was doubled over and groaning due to abdominal distension and pain. She was also somewhat lethargic. She had a thin build and a light complexion. Her vital signs were normal. Examination of the abdomen was precluded due to her discomfort. Standing postural analysis revealed a mild pelvic unleveling with a low left ilium and hypolordosis of the lumbar spine. Leg length findings using Thompson analysis revealed a short left leg with a positive Deerfield on the left.<sup>8</sup> Static and motion palpation of her cervical, thoracic, and lumbar spine revealed taut and tender muscle fibers around C1 on the right and L1 on the right, with restricted joint motion at these areas as well as tenderness to palpation over the right transverse processes of L1. A thermal scan<sup>9,10</sup> was performed and results showed a significant asymmetry in temperature in the thoracolumbar region.

A diagnosis of C1 and L1 subluxation with concurrent chronic constipation was made. Treatment was initiated after the initial evaluation. Full-spine diversified side posture manipulation was delivered to the L1 vertebral motion segment and then a supine diversified treatment was delivered to C1. The child returned the following day accompanied by her mother. There was a dramatic change in her disposition and activity. Her mother reported that a couple of hours after the adjustment the child had a successful and large bowel movement “unlike any she had ever had”. Her abdominal distention and gas also resolved. She was no longer bent over in pain, instead was jumping up and down and very happy to report her progress to the author. Over the course of 2 weeks the child was adjusted 6 times and the mother stopped giving the child Miralax. She continued improved bowel function as reported by her mother and now averaged 2-3 bowel movements per week which were larger in size, softer in consistency and non-painful. Due to the holidays there was a discontinuation in treatment upon which the patient returned with slowed bowel function albeit not as bad as previously reported. She once again reported improvement in bowel function after

### Frequency and Consistency of Bowel Movements

Timeframe	Frequency	Consistency
Prior to Chiropractic	1X per week	Small, hard, pellet-like
During Treatment	2-3X per week	Larger, softer
After Treatment	4-5X per week	Larger, softer

**Table 1.**

resuming treatment. Again, due to family scheduling conflicts there was a gap in treatment of a month during which her bowel movements slowed. At that time a re-evaluation was conducted which showed an improved thermal scan.

The patient resumed active care and was seen a total of 6 times over the course of the next 4 weeks. During this time she continued to show signs of improved bowel function with 3-4 bowel movements per week (without Miralax) which were larger, softer and less painful. The patient’s mother provided positive, although anecdotal, evidence that “the patient had normal bowel movements for the first time in her life”. She was released from care and advised to continue as needed. Three months have elapsed and a follow-up with her mother revealed she continues to have regular bowel movements with a frequency averaging 4-5 times per week.

### Discussion

Normal bowel movements are essential for good health. The nervous system, diet, disease, medication and psycho-social factors influence gut motility. Constipation is a significant problem in the pediatric population. It accounts for 5% of all outpatient visits to pediatricians and 25% to gastroenterologists.<sup>11,12</sup> The child here had a lifelong history of chronic constipation, with an acute flare-up of gas, abdominal pain and distension. She had relief of her symptoms and a significant bowel movement shortly after her first adjustment. During the 6 week course of chiropractic care she averaged 2-3 bowel movements per week which were larger, softer and non-painful without medication. Since no other therapies were administered around the time of the chiropractic treatment the ensuing discussion will focus on the potential effects of treatment.

The autonomic nervous system regulates the actions of organs, glands and blood vessels. The sympathetic innervation to the large intestine, through the proximal two thirds of the transverse colon, is carried by thoracic splanchnic



nerves (primarily the lesser thoracic splanchnic from T-10 to T-11). The distal third of the transverse colon, descending colon, sigmoid colon, rectum, and upper part of the anal canal receive their sympathetic innervation from the lumbar splanchnic nerves, which arise from lumbar levels of the sympathetic trunk. Both the thoracic and lumbar splanchnic nerves carry preganglionic fibers, which synapse in pre-vertebral ganglia associated with the celiac, superior mesenteric, inferior mesenteric, and superior and inferior hypogastric plexuses. Postganglionic fibers then pass to the viscera along periarterial plexuses.<sup>13,14</sup>

In the present case taut and tender muscle fibers around the L1 vertebra with restricted joint motion were noted. The initial thermal scan showed significant temperature asymmetry in the thoracolumbar region. The follow-up thermal scan showed much improved thermal symmetry in the thoracolumbar region. Uematsu et al determined normative values for skin temperature differences based upon asymptomatic "normal" individuals.<sup>10</sup> The authors stated, "These values can be used as a standard in assessments of the sympathetic nerve function, and the degree of asymmetry is a quantifiable indicator of dysfunction.... Deviations from the normal values will allow suspicion of neurological pathology to be quantitative and therefore can improve assessment and lead to proper clinical management." It is possible that by alleviating the segmental dysfunction through the adjustment, the colon function was positively affected.

Case studies, due to the nature of their design, are limited with regard to conclusions that can be drawn from them. The management of patients in an outpatient setting occurs primarily in an uncontrolled environment, and due to these factors, the care rendered to one patient may not produce the same result in another patient. The present study does not prove that chiropractic manipulation was what improved her bowel function. But the dramatic improvement in bowel function after the patient's first treatment suggests that controlled clinical trials of the chiropractic management of childhood constipation may be warranted.

## Conclusion

This case adds to the other documented cases where there appears to be a temporal association between chiro-

practic manipulation and the improvement of bowel movements. The patient continues to have 4-5 bowel movements per week which are larger, softer and non-painful. Further research needs to be performed to substantiate the benefit of chiropractic manipulation in cases of constipation in the pediatric population.

## Acknowledgements

I wish to acknowledge the patient and her mother for allowing her case to be presented.

## References

1. Loening-Baucke V. Prevalence rates for constipation and faecal and urinary incontinence. *Arch Dis Childhood*, 2007; 92:486-489.
2. Borowitz SM, Cox DJ, Tam A, Ritterband LM, Sutphen JL, Penberthy JK. Precipitants of constipation during early childhood. *J Am Board Fam Pract*. May-June 2003; 16(3):213-8.
3. Guyton AC, Hall JE. *Textbook of Medical Physiology, 11th ed.* Philadelphia: Elsevier Saunders; 2006:771-9, 822.
4. Hewitt, EG.; Chiropractic Treatment of a 7-Month-Old With Chronic Constipation: A Case Report. *Chiropractic Technique* 1993; 5(3):101-103.
5. Eriksen K. Effects of upper cervical correction on chronic constipation. *Chiropr Research J*, 1994; 3(1):19-22.
6. Marko SK. Case study: The effect of chiropractic care in an infant with problems of Constipation. *Chiropr Pediatrics* 1994; 1:23-24.
7. Alcantara J, Mayer DM. The successful chiropractic care of pediatric patients with chronic constipation: a case series and a review of the literature. *Clinical Chiropr* 2008;11:138-147.
8. Cooperstein R. Thompson Terminal Point Technique. *J Chiropr Techniques* 1995;7(2): 60-63.
9. Korr IM. *The Collected Papers of Irvin M. Korr*. American Academy of Osteopathy. Indianapolis, IN. 1979.
10. Uematsu S, Edwin DH, Jankel ER, et al. Quantification of thermal asymmetry." *J Neurosurgery* 1988; 69:552.
11. Baker SS, Liptak GS, Coletti RB, Croffie JM, Di Lorenzo C, Ector W, et al. Constipation in infants and children; evaluation and treatment. A medical position statement of North American society for pediatric gastroenterology and nutrition. *J Pediatr Gastroenterol Nutr* 1999; 29:612-6.
12. Abi-Hanna A, Lake AM. Constipation and encopresis in childhood. *Pediatr Rev* 1998; 19:23-30.
13. Moore KL, Dalley AF. *Clinically Oriented Anatomy*. 5th ed. Philadelphia: Lippincott, Williams, and Wilkins; 2006. P. 321-5.
14. Standring S, editor. *Gray's Anatomy: The Anatomical Basis of Clinical Practice, 39th ed.* London: Elsevier; 2005 p. 1184-6.



# Chiropractic Care of Infant with Down Syndrome: A Case Report

Rachael A. Kuperus, DC, Rebekah A. Wittman, DC, DACCP and Sharon Vallone, DC, FICCP

## ABSTRACT

**Introduction:** The following case report discusses an infant diagnosed with Down Syndrome (DS) Trisomy 21 and the observed benefits she received by including chiropractic adjustments and cranial sacral therapy in her health care plan.

**Case Presentation:** A female infant presented to Kentuckiana Children's Center (KCC) with maternal concerns of failure to gain weight and thrive, as well as dysfunctional breastfeeding. The child's treatment plan at KCC consisted of full spine chiropractic adjustments, cranial sacral therapy and Kinesiotaping. The infant also received physical therapy at an outpatient facility other than KCC, as well as being supplemented with additional colostrums.

**Intervention and Outcomes:** After one year of care, the child had achieved her developmental milestones on the higher range of predicted normal for Down Syndrome (DS) infants. Her height and weight were consistently around the 50th percentile for infants with DS.

**Conclusion:** The combined approach of chiropractic and cranial sacral therapy may have contributed to the overall improvement in health and developmental maturation of this infant at the end of her first year, although it is difficult to draw conclusions based on one case, where multiple treatments were utilized. Further research is warranted to determine the effectiveness of the inclusion of chiropractic care in the health care team of an infant diagnosed with DS, and also differentiate the effects of chiropractic care without the influence of multiple interventions.

**Keywords:** Down Syndrome, Trisomy 21, chiropractic, adjustments, Kentuckiana Children's Center

## Introduction

Down Syndrome (DS) is a genetic disorder that presents with a wide spectrum of developmental challenges contributing to the overall health of the child, both physically and intellectually. According to the National Institutes of Health (NIH) and the Centers for Disease Control (CDC), Down Syndrome occurs in 1 out of 800 live births or in 3,359 births per year in the United States.<sup>1,2</sup> There are three types of this chromosomal disorder. The most prevalent type, Trisomy 21, accounts for 92% of cases and occurs when an additional chromosome 21 is present in every cell. The second type is Mosaic Trisomy 21, which accounts for 2-4%. In this instance, a portion of the cells are normal and portions have an additional chromosome. The extent of associated conditions that may occur are proportional to the amount of cells that present with an additional chromosome.<sup>1</sup> Robertsonian Translocation

Trisomy 21, the third type, occurs when one chromosome 21 is attached to other chromosomes. In this case there is an additional chromosome 21 on the translocated chromosome. This does not occur on each cell and again, the extent of physical and developmental problems that arise are related to the number of cells affected.<sup>1,3</sup>

Research has recognized maternal age as a long-standing factor in the increased risk of Trisomy 21; however research also makes a correlation between increased age and increased exposure to environmental insults. These environmental insults may affect the stability of the ovary and oocyte over time, resulting in an increased rate of infants born with Down Syndrome to older women.<sup>4</sup> The NIH reports 75% of Down Syndrome babies are born to women under the age of 35, yet the chances that a woman over the age of 35 will have a child with DS is greater because less women in this age group are giving birth. At the age of 25 a woman's chances of having a baby with DS are 1:1250. At the age of 40 her chances are 1:100.<sup>1</sup>

Diagnosis is often made prior to birth. Patients over the age of 35 are typically encouraged to undergo chorionic villus sampling and amniocenteses. Women under the age of 35 are recommended to undergo maternal serum screening for alpha-fetoprotein, unconjugated estriol and human chorionic gonadotropin. These tests screen for Down

---

**Rachael Kuperus, DC**

*Clinic staff doctor, Kentuckiana Children's Center  
Louisville, Kentucky, USA*

**Rebekah A. Wittman, DC, DAACP**

*Private practice, Richland, Indiana, USA*

**Sharon Vallone, DC, FICCP**

*Private Practice, Tolland, Connecticut, USA*

*Corresponding author: Dr.rachaelk@gmail.com*

Syndrome, but are not fool proof.<sup>3,5</sup> A newer screening test reports an 85% detection rate of Down Syndrome. In this test, fetal anomalies may be identified as early as 11 weeks by a sonographic measurement of nuchal translucency.<sup>6</sup> The physical features of a neonate born with Down Syndrome are most often recognizable at birth and may include a simian crease, hypotonia, flattened face with oblique palpebral fissures, shortened neck with increased skin at the posterior aspect of the cervical spine, brushfield spots, low set ears, a protruding tongue and high arched palate.<sup>3</sup> A chromosomal karyotyping will confirm a diagnosis if prenatal diagnostic tests were not performed or were inconclusive. This will further differentiate the type of Down Syndrome.

Children with Down Syndrome are typically assessed for a myriad of associated medical problems at birth. Heart defects are common in 40 to 60% of Down Syndrome cases, with atrioventricular canal defects, ventricular septal defects and tetralogies of Fallot, being the most common.<sup>7</sup> Gastrointestinal anomalies are also common, and may include esophageal atresia, tracheoesophageal fistula, pyloric stenosis and Meckel's diverticulum. Hypotonia may contribute to gastroesophageal reflux, feeding difficulties and constipation. Abnormalities in the development of the ears, nose, and throat, along with hypotonia, often lead to an increased incidence of otitis media and upper respiratory infections. Orthopedic concerns include ligament laxity, which contributes to the increased incidence of atlanto-axial instability and congenital hip dysplasia.<sup>7</sup> Cranial misalignments, hypotonia, and macroglossia may negatively affect the suck-swallow reflex.<sup>8</sup>

The American Academy of Pediatrics has specific guidelines for the care and health supervision of the child with Down Syndrome. These guidelines include timetables for specific screenings, DS specific height and weight charts, as well as general recommendations for health.<sup>9</sup> Chiropractic examination and care is not included in health recommendations for these children. A search of Pubmed and Index to Chiropractic Literature using the key words "chiropractic" and "Down Syndrome" produced 4 articles.<sup>10-13</sup>

### Case Report

A six-day-old Caucasian female presented to Kentuckiana Children's Center (KCC). The infant had been diagnosed with Down Syndrome Trisomy 21 by karyotype testing.

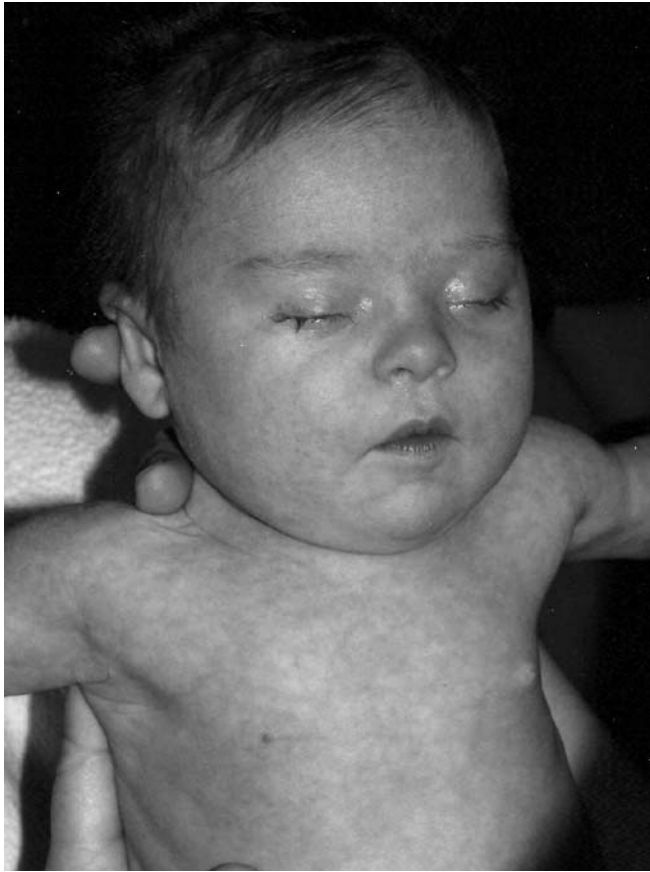### Maternal and neonatal history

The mother of the patient had been in a car accident early in the pregnancy and sought treatment for right sciatic

and low back pain. The pregnancy had been stressful for the mother because of a difficult home situation between herself and the infant's father. The mother received prenatal care including pre-natal vitamins with iron and ultrasounds were performed each trimester. The ultrasounds had demonstrated short femurs. The mother had denied follow up maternal serum screening or any other testing. She denied drinking alcohol, smoking tobacco or taking any other medications during pregnancy. She received weekly chiropractic and cranial sacral therapy at KCC the last six weeks before giving birth.

The patient was delivered vaginally at 39 weeks gestation in a hospital facility. The mother reported 12 hours of difficult labor. She experienced significant back pain due to the occiput posterior presentation of the fetus. APGAR scores were 8 and 9 at one minute and five minutes respectively. Birth weight was 7lbs. 7ozs. and length was 21.5 in. Head circumference was 33 cm. It was noted after birth that the neonate had several facial features that were suggestive of Down Syndrome including wide set eyes, epicanthal folds, low set ears, fifth finger clinodactyly, a large gap between the great and 2nd toe and hypotonia. The parents declined the Hepatitis B vaccine. An echocardiogram on day 2 revealed a small patent foramen ovale and small patent ductus arteriosus. The cardiologist's opinion was that this would resolve on its own. A chromosome analysis on day 3 confirmed a diagnosis of Trisomy 21. The neonate demonstrated reduced hearing on the left upon audiologic evaluation. A follow-up 10 days later showed minimal, bilateral hearing loss at the highest range. The patient was released from the hospital after 2 days and was referred for occupational and physical therapy. The parents were referred to a local Down Syndrome support group.

Upon initial presentation of the neonate to our office for a new patient exam, the mother's primary concern was that the child consistently gain weight and thrive. The neonate was having some difficulty staying awake while nursing at the breast. She was breastfeeding exclusively for 10 minutes at a time, one breast per feeding. The mother reported she would not wake after falling asleep. The mother would pump the rest of the breast milk and try to save it for later use. The breast milk was not being used because the baby would refuse the bottle. No latching or suckling difficulties were reported other than the aforementioned inability to stay awake at the breast. The mother had also pumped and saved her initial colostrum, she was administering them via dropper. The infant was sleeping well and having daily bowel movements. Head control and low muscle tone were of secondary concern.



**Figure 1. Patient at first visit.**

The child's family history included an older sister of 18 months in good health. The mother was 36 years of age with a history of endometriosis and a surgical history of a right ovarian cyst removal. The father was 32 years old with a history of drug and alcohol abuse as well as a cigarette smoker. He wore leg braces as a child. It is unknown why or for how long.

### Physical Exam

A complete physical exam was performed by an experienced chiropractic pediatric physician. The exam included vitals, EENT, percussion and auscultation of the chest and abdomen and chiropractic exam which included neurologic, orthopedic and palpatory findings. The neonate appeared to be content. The overall appearance of the neonate included a slight bluish hue to the skin. There were no markings, rashes or lesions present. The facial appearance was typical with characteristics of a broad nose and epicanthal folds. There was bilateral yellow green discharge from the eyes. Examination of the hands revealed normal digits and an absence of the simian crease from the palm. Scoliosis and sacral dimpling were not observable upon

visual inspection. The tongue was midline and did not protrude. There was no tongue tie. Movements and joint integrity of the hip, knee, foot, shoulders, elbow, hands as well as the cervical and lumbar spine were examined and found to be symmetrical and within normal ranges of motion. No ligamentous laxity was noted during joint examination. Joint play was comparable to that of a typical infant. Global hypotonia was noted.

Inspection and palpation of the chest and abdomen were normal. The thorax was short but symmetrical. Lymph nodes were soft. Some grunting noises were noted, but respiratory sounds were unlabored. Chiropractic cranial palpation and examination did not reveal gross asymmetries. No adjustment was performed at initial exam.

The neonate was not weighed at initial exam, but at the second visit at 2 weeks of age, she weighed 6 lbs and 12 ozs. She had lost 11 oz. since birth which was just under 10% of her birth weight. Figure 1 shows the patient at her first visit, and Figure 2 shows the patient at approximately one year of age.

### Intervention and Outcomes

A care plan was recommended for this child diagnosed with Down Syndrome with the goals of supporting



**Figure 2. Patient at approximately one year of age.**

Activity	Patient	Average child with DS	Range for Child with DS
Head control	3 weeks	5 months	3-8.5 months
Reacts to sound	1 month	1 month	0.5-1.5 months
Smiles when talked to	1 month	2 months	1.5-4 months
Support body on arms when prone	3 months	6 months	3-10 months
Rolls over	5 months	8 months	4-12 months
Takes solids well	5 months	8 months	5-18 months
Hand to foot play	7 months	7 months	4-10 months
Sits without support	10 months	9 months	6-16 months
Says "mama"	11 months	11 months	7-18 months

**Table 1. Patient milestones compared to normal ranges.**

development in hopes of minimizing some of the challenges typically associated with Down Syndrome, as well as addressing inefficient milk transfer while breastfeeding and poor weight gain. Care in this case included chiropractic spinal and cranial sacral therapy. For one month the child was evaluated and treated once weekly with chiropractic adjustments only. Because the child was hypotonic, the chiropractor felt it best to see her at this frequency, to evaluate and determine if an adjustment needed to be given. Adjustments were determined by passive range of motion examination and static palpation. At the second visit, a posterior sacrum was noted and adjusted with a posterior to anterior press and hold for several seconds followed by a light thrust. At visits 2-4, the patient presented with occiput posterior-superior subluxation on the right (PS-RS). A gentle pressure was applied for several seconds, while the infant was supine to release the occiput with inferior and anterior direction. The quantity of colostrums administered was increased to support immune function and encourage weight gain. At the end of three weeks the child was gaining weight, sleeping for longer periods of time and not falling asleep while nursing. After one month, the mother reported the infant's feeding sessions at the breast were lasting for thirty to forty minutes without falling asleep.

At one month, care was decreased to every 2-3 weeks. Treatment with cranial sacral therapy was implemented to address the lack of lateral head growth, as well as restrictions in the vomer, ethmoid, sphenoid and maxilla. The child was weighed at each office visit to monitor growth. Throughout the first six months she typically presented with occiput or atlas and sacral subluxations. Atlas was adjusted with the infant in a supine position. The doctor contacted the

tip of the atlas transverse on the side of laterality with the 5th digit. While applying a gentle lift of the occiput on the opposite side as a stabilizing hand, the doctor's 5th digit applied several high velocity, low amplitude impulses, lateral to medial.

At 7 months, a significant posteriority of the L4 spinous was noted. The patient was rolling from stomach to back and back to stomach and was able to prop herself up on her arms; but was unable to sit unassisted. When she was placed in a seated position, she did not have the core strength to support herself and required assistance from falling forward. She slouched at the mid to lower lumbar area. There was a loss of lumbar extension upon passive range of motion exam. Her treatment team felt this was due to the poor muscular tone and lack of strength developing in the lumbar extensors as well as overall poor core strength. The treatment team addressed this with Kinesiotape to facilitate lumbar extensors and adjustments of the L4 with a posterior to anterior, press and hold for several seconds followed by a light thrust. Kinesiotape was applied in two parallel strips along the lumbar and lower thoracic paraspinal muscles. The base was laid directly above the sacrum and applied with minimal stretch in a superior direction.<sup>14</sup>

After one year of care, the child had achieved her developmental milestones, consistent with the guidelines set forth for Down's syndrome children by the National Down Syndrome Society and Down Syndrome Education International.<sup>15,16</sup> Although this patient did not exceed the milestone guidelines, the range for DS infants cover a broad range of time. As shown in Table 1, this child was consistently achieving in the higher range of the predicted normal, achieving her goals at an earlier age. Her height was

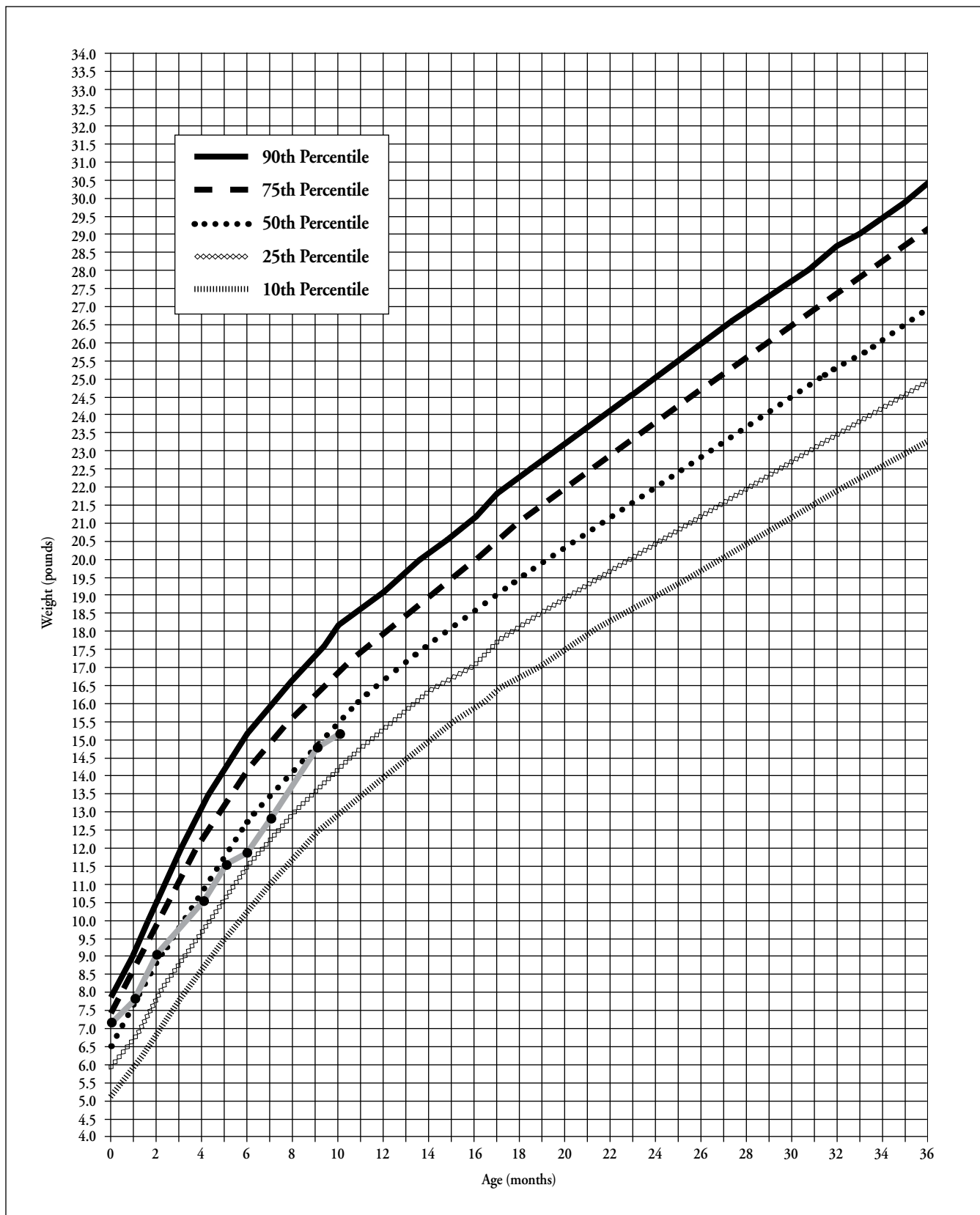


Figure 3. Growth chart for girls with Down Syndrome.

typically around the 60th percentile for females with Down Syndrome. Weight consistently increased and remained steadily around the 50th percentile for Down Syndrome females (see Figure 3).<sup>9</sup>

After one year of regular chiropractic and cranial sacral therapy the child's cranial and facial shape appeared balanced and symmetrical. She did not protrude her tongue and breathing was unlabored and with very minimal congestion. During the course of treatment at KCC, she was on antibiotics twice in the first year for upper respiratory infections, once at 5 months and once at 11 months. Core strength, specifically of the lumbar area improved so she was able to sit on her own by 10 months.

The patient received supplemental physical therapy beginning at 6 weeks of age and continuing through the first year. Therapy was provided once every 2 weeks for 50 minutes in her home. The therapist focused on building muscle strength by utilizing activities the family could incorporate in the patient's daily routines.

No adverse events were reported as a result of chiropractic adjustments or cranial sacral therapy.

## Discussion

When a diagnosis of Down Syndrome is made, it is difficult to predict either the full potential or the extent of disability a neonate may face. Each child is an individual case and the associated medical conditions can be vast. This case report proposes that chiropractic care may have a positive impact on the overall wellness of the child diagnosed with Down Syndrome and possibly reduce the complicating factors and conditions he or she may face that may interfere with timely attainment of developmental milestones.

Fallon (2005) defined the role chiropractic plays in the health care of the pediatric population. In her paper she noted, "of all the categories which are overlooked is the one with the child who has permanent disability and who requires care for that disability on a regular basis. Children in this category often appear as though they are receiving maintenance care, but this care should not be considered maintenance but essential to their health and well-being as their disability often induces subluxation on a regular basis."<sup>17</sup>

There are several reasons why a child with special needs may subluxate more frequently. In the case of Down Syndrome, there are contributing factors which may include

hypotonicity, the possibility of an atlanto-axial instability due to vertebral anomalies or ligamentous laxity of the alar and transverse ligaments, overall ligament laxity, muscular weakness and cranial restrictions.<sup>18-20</sup> Chiropractic care is modified for the pediatric patient's specific developmental anatomy and in the case of a pediatric patient with special needs, the congenital and anatomical factors are considered while implementing treatment.<sup>18-20</sup> In working with a child with Down Syndrome, for example, rotation was avoided during the adjustment in the upper cervical spine. Instead, gentle, direction specific traction was substituted. Reverse fencer, a common chiropractic procedure performed on infants to determine atlas subluxation was not utilized due to the risk of atlanto-axial instability.

Many of the complicating issues that are routinely associated with the diagnosis of Down Syndrome have the potential to be positively impacted by the chiropractic adjustment. Of particular interest in the first year of life is feeding issues. The difficulty with breastfeeding involves many factors. A high palatine arch, macroglossia, protruding tongue, low muscle tone, maxillary and mandibular changes, a poor or absent suck-swallow reflex or impaired suck/swallow/breath synchrony, cranial restrictions, and subluxation of the cervical spine may all negatively affect the DS neonate's ability to feed, especially at the breast.<sup>8,21</sup> In this case we speculate that subluxation of the occiput resulted in impaired nerve supply, and combined with hypotonia as a potential cause of inefficient feeding. Others speculate, when the occiput is subluxated it can interfere with the firing of the glossopharyngeal Nerve (CNIX) and vagus Nerve (CN X) as they exit the jugular foramen, as well as the Hypoglossal Nerve (CN XII) as it exits the hypoglossal canal.<sup>8</sup> These cranial nerves innervate the muscles utilized in the suckling response.,

Breastfeeding is particularly important for infants with DS for the benefits of passive immunity, as they are often prone to upper respiratory infections, otitis media, failure to thrive, and obesity later in life. Breastfeeding encourages growth, wellness of the child and bonding with the mother, yet studies have shown Down Syndrome infants are less likely to be breastfed than typical infants.<sup>21,22</sup> Case series suggest breastfeeding difficulties may be effectively managed conservatively with chiropractic care.<sup>8,23</sup>

Infants with DS are prone to chronic respiratory tract infections and otitis media. Mucus drainage can be problematic as the sinuses are poorly developed and the shape of the cranium is not ideal for drainage. Lymphatic stasis,

poor development of cervical spine musculature, cervical spine subluxation, difficulty breastfeeding, impaired immune function, a shortened cochlea, and hypotonicity of the musculature that drains the Eustachian tube such as the tensor veli palatine and tensor tympani, can all contribute to the increased risk of otitis media. Medical management of otitis media such as tympanostomy and antibiotic therapy show no better outcome than conservative care.<sup>24,25</sup> Hearing loss is a concern and tube insertion is often recommended prematurely to infants with DS, yet research has shown there is not improvement in hearing acuity after tympanostomy tube insertion and the child with DS has been shown to have a less favorable outcome than the typical child after tube insertion.<sup>24</sup> Further study may show that conservative management of these issues with the chiropractic adjustment, lymphatic drainage, and cranial sacral therapy may be more effective than antibiotic therapy and surgical intervention.<sup>25</sup>

## Conclusion

Chiropractic care may play an effective role in the management and care of conditions associated with a diagnosis of Down Syndrome. There has been little research published on the benefits of chiropractic care for the DS infant. In this specific case, there were no negative consequences observed, as a result of cranial sacral therapy and the chiropractic adjustment. It is important to note that ranges that have been set forth as normal development for the child with DS are large. In this case the infant was consistently on the higher end of the normal range. This is one case study in which positive outcomes were seen, although other therapy and treatments were used in conjunction with chiropractic care to obtain results. Further limitations in this study include a lack of empirical data published on this topic. The mechanisms describing the effect of the chiropractic adjustment on breastfeeding difficulties as well as otitis media; and the effects of addressing cranial restrictions with cranial sacral therapy have not been adequately explored in research studies. More research is necessary to further explore these mechanisms. Future research is needed to examine the specific effects of chiropractic care, without the influence of outside therapy and treatments; and the long term effects these changes may have on the overall health and wellness of the DS child when care is begun at birth.

## References

1. National Institute of Health [Internet] Bethesda, MD: Facts about Down Syndrome. [cited 2010 July 19]. Available from <http://www.nichd.nih.gov/publications/pubs/downsyndrome.cfm>.
2. Centers for Disease Control and Prevention [Internet]. Atlanta: Facts about Down Syndrome [updated 2011 Feb 25; cited 2011 May 2]. Available from <http://www.cdc.gov/ncbddd/birthdefects/DownsSyndrome.html>
3. Newberger D. Down Syndrome: prenatal risk assessment and diagnosis. *Amer Family Physician* 2000; 62:825-32,837-8.
4. Lamb N, Yu K, Shaffer J, Feingold E, Sherman S. Association between maternal age and meiotic recombination for Trisomy 21. *Amer J Human Genet* 2005; 76:91-99.
5. Benn PA. Advances in prenatal screening for Down Syndrome: II first trimester testing, integrated testing and future directions. *Clin Chim Acta* 2002; 324(1-2):1-11.
6. Hourrier S, Salomon LJ, Dreux S, Muller F. Screening for adverse pregnancy outcome at early gestational age. *Clin Chim Acta* 2010; 411(21-22):1547-1552.
7. Weijerman M, de Winter J. Clinical practice, the care of children with Down Syndrome. *Eur J Pediatr* 2010; 169:1445-1452.
8. Vallone S. Chiropractic evaluation and treatment of musculoskeletal dysfunction in infants demonstrating difficulty breastfeeding. *J Clin Chirpr Pediatr* 2004; 6 (1): 349-368.
9. American Academy of Pediatrics Committee on Genetics. Health supervision for children with Down Syndrome. *Pediatrics* 2001; 107:442-449.
10. LaFrancis, M. A chiropractic perspective on atlantoaxial instability in Down's Syndrome. *J Manipulative Physiol Ther* 1990; 13(3):157-160.
11. McMullen, M. Handicapped infants and chiropractic care: Down Syndrome-Part 1. *ICA Internat Rev Chiropr* July/August 1990.
12. Mirtz A, Ratliff CR, Reno ME. Atlantoaxial instability in Down's Syndrome: the role of chiropractic in special olympic participation. *Chiropr Sports Med* 1989 Sept; 3(3):81-84.
13. Clum GW. Atlanto-Axial subluxation in Down's Syndrome: its importance to chiropractic practice. *Today's Chiropractic* 1985 May/June; 14(2):33-36.
14. Kinesiotaping in Pediatrics. *Fundamentals and Whole Body Taping*. Kinesio USA, LLC; 2006.
15. National Down Syndrome Society. Developmental milestones chart. New York, NY: National Down Syndrome Society, 2011. Available at <http://www.ndss.org>
16. Down Syndrome Education International. An overview of the development of infants with Down Syndrome (0-5 years). Down Syndrome Education Online; 2001. Available at <http://www.downsyndrome.org>.
17. Fallon, J. The child patient: a matrix for chiropractic care. *J Clin Chiropr Pediatr Suppl* 2005; 6(3): 1-14.
18. Handoll N. The osteopathic management of children with Down Syndrome. *Br Osteopathic J* 1998; 21:11-20.
19. Vallone S., Fysh P, Tanis L. First do no harm-chiropractic care and the newborn. *J Clin Chiropr Pediatr* 2009; 10(2):647-654.
20. Vallone S. Miller J, Larsdotter A, Barham-Floreani J. Chiropractic approach to the management of children. *Chiropr Osteopathy* 2010; 18(16).



21. Lewis E, Kritzinger A. Parental experiences of feeding problems in their infants with Down Syndrome. *Down Syndrome Research and Practice* 2004; 9(2):45-52.
22. Pisacane A, Toscano E, Pirri I, Continisio P, Andria G, Zoli B, et al. Down Syndrome and breastfeeding. *Acta Paediatr* 2003; 92:1479-1481.
23. Miller J, Miller L, Sulesund A, Yevtushenko A. Contribution of chiropractic therapy to resolving suboptimal breastfeeding: a case series of 114 infants. *J Manipulative Physiol Ther* 2009; 32:670-674.
24. Iino Y, Imamura Y, Harigai S, Tanaka Y. Efficacy of tympanostomy tube insertion for otitis media with effusion in children with Down Syndrome. *Int. J. Pediatr. Otorhinolaryngol* 1999; 49:143-149.
25. Fallon J. The role of the chiropractic adjustment in the care and treatment of 322 children with otitis media. *J Clin Chiropr Pediatr* 1997; 2:167-183.



# Abstracts of Interest

---

**House Simon H. Nurture of the brain, nutritional & emotional, in the context of evolution and the lifecycle. *J Prenatal and Perinatal Psychology and Health* Spring 2010; 24 (3): 130-157.**

**ABSTRACT:** Controlled trials reveal that, from before conception, nutrient deficits and toxins affect sperm, ovum, and maternal stores, lastingly impairing a child's health and abilities. Deficits, toxins, and stress can inhibit structure and function, and be linked to autism or reduced self-control, possibly with violent tendencies. From the beginning, epigenetic settings are mostly set early for directing development according to current environment. Many are operative in the brain. Nutritional diversion from our evolutionary path, too sudden for genetic adaptation, is resulting in pandemics including mental disorders, cardiovascular problems, obesity, and diabetes. Understanding and practice of nutritional and emotional nurture round the lifecycle helps to fulfill genetic potential. Tracing from the Big Bang, the emergence of elements, nutrients, and cells, providing for the diversity of evolving life, we can see ourselves in context and the biosphere's and our own mutual needs. Vital to both to meet prime needs is a further agricultural revolution, this time of estuary and ocean beds. This article presents the scientific basis for urgent action in this area.

---

**Mckillop E, Martin S, Bowen A, Mhajarine N. The Best and Worst Time of My Life: The Lived Experience and Meaning of Pregnancy in Women with Mild to Moderate Depression. *J Prenatal and Perinatal Psychology and Health* March 2010; 24(3): 174-196.**

**ABSTRACT:** The notion that pregnancy can, for some women, be a time of unhappiness and depression has only recently been recognized in media and by the general public. Although researchers and clinicians have begun to study antenatal depression with regards to prevalence, associated factors, and treatment approaches and outcomes, less is known about women's lived experience of this phenomenon. A hermeneutic phenomenological study was conducted with six pregnant women who scored 10, 11, or 12 on the Edinburgh Postnatal Depression Scale, indicating mild to moderate symptoms of depression. Participants were interviewed individually regarding their experiences of depression during pregnancy. Data generated in the form of transcripts were analyzed and five themes emerged: disconnection vs. new connection and/or reconnection; loss of identity vs. new identity; fatigue

and illness vs. vitality and wellness; anxiety and insecurity vs. confidence and security; and sadness and hopelessness vs. joy and expectation. The overarching shared meaning of these experiences was ambivalence. Findings provided rich, thick descriptions of the lived experience and meaning of antenatal depression. Future research and implications for counseling practice are discussed.

---

**Chamberlain David B. The Sentient Prenate: What Every Parent Should Know. *J Prenatal and Perinatal Psychology and Health* January 2011; 26 (1): 37-59.**

**ABSTRACT:** In the 1980's parents in large numbers were first introduced to the sensitive, perceptive, conscious, and cognitive prenatate. This paper summarizes the evidence from major research findings, demonstrating that prenatates are 1) sensitive and aware, 2) learn and dream, and 3) are social and communicative. Well-designed experimental programs in prenatal enrichment confirm the intelligence and receptivity of womb babies. A closing section describes the special resources now available to parents who want to deliberately enhance prenatal bonding and communication.

---

**Buryk M, Bloom D, Shope T. Efficacy of neonatal release of ankyloglossia: a randomized trial. *Pediatrics* 2011; 128(2):280-8 (ISSN: 1098-4275).**

**BACKGROUND:** Ankyloglossia has been associated with a variety of infant-feeding problems. Frenotomy commonly is performed for relief of ankyloglossia, but there has been a lack of convincing data to support this practice. **OBJECTIVES:** Our primary objective was to determine whether frenotomy for infants with ankyloglossia improved maternal nipple pain and ability to breastfeed. A secondary objective was to determine whether frenotomy improved the length of breastfeeding. **METHODS:** Over a 12-month period, neonates who had difficulty breastfeeding and significant ankyloglossia were enrolled in this randomized, single-blinded, controlled trial and assigned to either a frenotomy (30 infants) or a sham procedure (28 infants). Breastfeeding was assessed by a preintervention and postintervention nipple-pain scale and the Infant Breastfeeding Assessment Tool. The same tools were used at the 2-week follow-up and regularly scheduled follow-ups over a 1-year period. The infants in the sham group were given a frenotomy before or at the 2-week follow-up if it was desired. **RESULTS:** Both groups demonstrated statistically significantly decreased pain scores after

the intervention. The frenotomy group improved significantly more than the sham group ( $P < .001$ ). Breastfeeding scores significantly improved in the frenotomy group ( $P = .029$ ) without a significant change in the control group. All but 1 parent in the sham group elected to have the procedure performed when their infant reached 2 weeks of age, which prevented additional comparisons between the 2 groups. **CONCLUSIONS:** We demonstrated immediate improvement in nipple-pain and breastfeeding scores, despite a placebo effect on nipple pain. This should provide convincing evidence for those seeking a frenotomy for infants with significant ankyloglossia.

**Sarris J, Kean J, Schweitzer I, Lake J. Complementary medicines (herbal and nutritional products) in the treatment of Attention Deficit Hyperactivity Disorder (ADHD): a systematic review of the evidence. *Complement Ther Med* 2011 Aug;19(4):216-27. doi: 10.1016/j.ctim.2011.06.007. Epub 2011 Jul 26.**

**OVERVIEW:** Complementary and Alternative Medicines (CAMs) are frequently given to children and adolescents for reputed benefits in the treatment of hyperkinetic and concentration disorders such as Attention Deficit Hyperactivity Disorder (ADHD). In such vulnerable populations high quality evidence is required to support such claims. **AIMS:** The aim of the paper is to assess the current evidence of herbal and nutritional interventions for ADHD using a systematic search of clinical trials meeting an acceptable standard of evidence. **METHODS:** PubMed, PsycINFO, Cochrane Library and CINAHL were searched up to May 26th, 2011 for randomised, controlled clinical trials using CAM products as interventions to treat ADHD. A quality analysis using a purpose-designed scale, and an estimation of effect sizes (Cohen's  $d$ ) where data were available, were also calculated. **RESULTS:** The review revealed that 16 studies met inclusion criteria, with predominant evidentiary support found for zinc, iron, *Pinus marinus* (French maritime pine bark), and a Chinese herbal formula (Ningdong); and mixed (mainly inconclusive) evidence for omega-3, and l-acetyl carnitine. Current data suggest that *Ginkgo biloba* (ginkgo), and *Hypericum perforatum* (St. John's wort) are ineffective in treating ADHD. **CONCLUSION:** The research suggests only some CAMs may be beneficial in ADHD, thus clinicians need to be aware of the current evidence. Promising candidates for future research include *Bacopa monniera* (brahmi) and *Piper methysticum* (kava), providing potential efficacy in improving attentional and hyperkinetic disorders via a combination of cognitive enhancing and sedative effects.

**Holmes AV, Auinger P, Howard CR. Combination feeding of breast milk and formula: evidence for shorter breast-feeding duration from the National Health and Nutrition Examination Survey. *J Pediatr* 2011; 159(2):186-91 (ISSN: 1097-6833)**

**OBJECTIVE:** To examine combination breast milk and formula-feeding (CBFF), defined as daily breast-feeding and formula-feeding begun in the first week of life and to examine associations between CBFF and overall breast-feeding duration. **STUDY DESIGN:** We used the National Health and Nutrition Examination Survey, 1999-2006, to determine the prevalence of CBFF in both univariable and multivariable analyses. We examined breast-feeding duration using Kaplan-Meier and Cox proportional hazards analyses. **RESULTS:** Among 6788 children ages 0-71 months, 8% were CBFF and 55% were exclusively breast-fed during the first week of life. Factors independently associated with CBFF were Hispanic ethnicity (adjusted OR, 3.81) and black race (adjusted OR, 2.59). CBFF was associated with decreased overall breast-feeding duration in the full cohort ( $P < .001$ ) but not in the Hispanic or black subgroups. CBFF and formula-feeding, when compared with 4 months of exclusive breast-feeding, were associated with an increased risk for overweight/obesity between ages 2 and 6 years. **CONCLUSIONS:** In a nationally representative sample, CBFF is associated with shorter overall breast-feeding duration in white but not Hispanic or black mother-baby dyads. A significant number of US infants, though breast-fed, do not receive the health benefits of exclusive breast-feeding. **PREMEDLINE IDENTIFIER:** 21429512

**Münstedt K, Thienel J, Hrogovic I, Hackethal A, Kalder M, Misselwitz B. Use of acupuncture and other CAM methods in obstetrics: an analysis of 409,413 deliveries from Hesse, Germany. *J Altern Complement Med* 2011 May;17(5):421-6. Epub 2011 May 9.**

**OBJECTIVES:** This study was done to analyze the frequency of use of acupuncture and other complementary and alternative medicine (CAM) methods during labor and to investigate the different characteristics of women being treated with or without acupuncture and CAM methods, as well as try to analyze birth-related outcome measures. **STUDY DESIGN:** Data were analyzed from 409,413 deliveries, registered between 2001 and 2008 by the agency for quality assurance in Hesse (the Hessian Perinatal Registry [HEPE] survey), which made up more than 95% of all deliveries in this German state during the given time period. **RESULTS:** Interest in the use of CAM seems to have de-

creased within the given time period. On average, acupuncture was used in 3.7% (15,345/409,295) of all deliveries and other CAM methods in 4.8% (19,507/409,295). The most important determinant for the use of one or both methods was the type of hospital. It was also found that German women with higher job qualifications were more likely to receive CAM treatment during delivery. Interestingly, application of CAM methods was associated with a higher use of analgesics during labor. The risk status of the pregnancy or the delivery was of minor importance. **CONCLUSIONS:** This analysis shows that the determinants of CAM use are similar to those in the field of oncology. In order to assess the efficacy of acupuncture or other CAM methods in the field of obstetrics, it seems necessary to extend the HEPE survey to cover these areas.

---

**Durmer JS, Quraishi GH. Restless legs syndrome, periodic leg movements, and periodic limb movement disorder in children. *Pediatr Clin North Am* 2011 Jun;58(3):591-620. doi: 10.1016/j.pcl.2011.03.005.**

**ABSTRACT:** The characteristic symptoms of restless legs syndrome (RLS) have been known for hundreds of years and were first reported in medicine in the 1600s. Clinicians must consider potential mimics, comorbid, and associated conditions when evaluating children with RLS symptoms. The traditional differentiation of RLS from periodic limb movement disorder (PLMD) is noted in children as well as adults. Because current pediatric RLS research is sparse, this article provides the most up-to-date evidence-based as well as consensus opinion-based information on the subject of childhood RLS and PLMD. Prevalence, pathophysiology, diagnosis, treatment, and clinical associations are discussed.

---

**Rayner JA, Willis K, Burgess R. Women's use of complementary and alternative medicine for fertility enhancement: a review of the literature. *J Altern Complement Med*. 2011 Aug;17(8):685-90. Epub 2011 Jul 6.**

**OBJECTIVES:** The use of complementary and alternative medicine (CAM) has increased in Western countries, with women identified as the primary users. Women's use of CAM in reproductive health is well documented; however, little is known about the use of CAM to enhance fertility, despite anecdotal evidence that this is a growing trend in reproductive medicine. The objective of this review was to examine the literature on women's use of CAM to enhance fertility, focusing on prevalence, motivations for use, and how information is sourced. **DESIGN:**

A systematic search of multiple databases was conducted using key words and selection criteria. **RESULTS:** A total of eight articles that met the selection criteria, published between 1990 and 2010, were found and included in the review. The articles were analyzed under five key themes: "user prevalence," "user profile," "motivation for use," "expectations and satisfaction," and "referral and information sources." This review demonstrates important gaps in the evidence regarding women's use of CAM for fertility enhancement. There are no population-based studies with representative samples, no commonly accepted definitions of CAM research, and few studies describing women's motivations for and experiences of using CAM for fertility enhancement. Importantly, little is known about women's sources of information about CAM in this context. **CONCLUSIONS:** Nationally representative, population-based studies are required to fill the gaps in the evidence, provide prevalence rates, and inform policy and clinical practice.

---

**Centers for Disease Control and Prevention (CDC). School health guidelines to promote healthy eating and physical activity. *MMWR Recomm Rep*. 2011 Sep 16;60(RR-5):1-76.**

During the last 3 decades, the prevalence of obesity has tripled among persons aged 6-19 years. Multiple chronic disease risk factors, such as high blood pressure, high cholesterol levels, and high blood glucose levels are related to obesity. Schools have a responsibility to help prevent obesity and promote physical activity and healthy eating through policies, practices, and supportive environments. This report describes school health guidelines for promoting healthy eating and physical activity, including coordination of school policies and practices; supportive environments; school nutrition services; physical education and physical activity programs; health education; health, mental health, and social services; family and community involvement; school employee wellness; and professional development for school staff members. These guidelines, developed in collaboration with specialists from universities and from national, federal, state, local, and voluntary agencies and organizations, are based on an in-depth review of research, theory, and best practices in healthy eating and physical activity promotion in school health, public health, and education. Because every guideline might not be appropriate or feasible for every school to implement, individual schools should determine which guidelines have the highest priority based on the needs of the school and available resources. **FREE FULL TEXT**

**Haemer M, Cluett S, Hassink SG, Liu L, Mangarelli C, Peterson T, Pomietto M, Young KL, Weill B. Building capacity for childhood obesity prevention and treatment in the medical community: call to action. *Pediatrics* 2011 Sep;128 Suppl 2:S71-7.**

Large gaps exist in the capacity of the US medical system to participate meaningfully in childhood obesity-prevention efforts and to meet the treatment needs of obese children. Current primary care practice for the prevention and treatment of childhood obesity often varies from evidence-based recommendations. Childhood obesity specialists have partnered successfully with schools of medicine, professional societies, and other organizations to collaboratively engage with primary care providers in quality improvement for obesity prevention and treatment. This review and commentary targets 2 audiences. For childhood obesity experts and their organizational partners, methods to support change in primary practice and the evidence supporting their use are outlined. For primary care providers and non-obesity specialists, effective strategies for changing practice and the potential benefits of addressing childhood obesity systematically are discussed. FREE FULL TEXT

**Keast DR, Rosen RA, Arndt EA, Marquart LF. Dietary modeling shows that substitution of whole-grain for refined-grain ingredients of foods commonly consumed by US children and teens can increase intake of whole grains. *J Am Diet Assoc* 2011 Sep;111(9):1322-8.**

**BACKGROUND:** Currently available whole-grain foods are not frequently consumed, and few children achieve the whole-grain intake recommendation. **OBJECTIVE:** To investigate the influence on whole-grain consumption of substituting whole-grain for refined-grain ingredients of foods commonly consumed by children. **DESIGN:** Secondary cross-sectional analysis of publicly available food consumption data collected by the US Department of Agriculture. **PARTICIPANTS/SETTING:** A nationally representative sample of US children aged 9 to 18 years (n=2,349) providing 24-hour dietary recall data in the 2003-2004 National Health and Nutrition Examination Survey. **MAIN OUTCOME MEASURES:** Whole-grain intake was modeled by replacing varying proportions of refined flour contained in foods such as pizza crust, pasta, breads, and other baked goods with whole-wheat flour, and by replacing a proportion of white rice with brown rice. Replacement levels were based on the acceptability of whole-grain foods tested among children in elementary schools, and ranged from 15% to 50%; the majority were  $\leq 25\%$ . **STATISTICAL ANALYSES PERFORMED:**

Sample-weighted mean premodeled and postmodeled whole-grain intake, standard errors, and statistical significance of differences between demographic subgroups were determined using SUDAAN (version 9.0.3, 2007, Research Triangle Institute, Research Triangle Park, NC). **RESULT:** Whole-grain intake increased 1.7 oz eq per day (from 0.5 to 2.2 oz eq/day). Premodeled and postmodeled whole-grain intakes were 6% and 28%, respectively, of total grain intake (7.7 oz eq/day). Major sources of postmodeled whole-grain intakes were breads/rolls (28.0%); pizza (14.2%); breakfast cereals (11.0%); rice/pasta (10.6%); quick breads such as tortillas, muffins, and waffles (10.8%); other baked goods (9.9%); and grain-based savory snacks other than popcorn (7.3%). Premodeled whole-grain intake differed by poverty level, but postmodeled whole-grain intake did not. **CONCLUSIONS:** The substitution of whole grain for a specific proportion of refined grain ingredients of commonly consumed foods increased whole-grain intake and reduced disparities between demographic subgroups of children and teens.

**Bauer KW, Laska MN, Fulkerson JA, Neumark-Sztainer D. Longitudinal and secular trends in parental encouragement for healthy eating, physical activity, and dieting throughout the adolescent years. *J Adolesc Health* 2011 Sep;49(3):306-11. Epub 2011 Feb 18.**

**PURPOSE:** Parental encouragement for healthy eating and physical activity has been found to be associated with the long-term healthy habits of adolescents, whereas parental encouragement to diet has been associated with disordered eating behaviors among adolescents. However, little is known about how parental encouragement changes as adolescents grow older (longitudinal trends), or how parental encouragement has changed over time (secular trends). This study examined 5-year longitudinal and secular trends in adolescents' report of their parents' encouragement to eat healthily, be physically active, and diet. **METHODS:** Project Eating Among Teens surveyed a cohort of Minnesota adolescents (n = 2,516) in the years 1999 and 2004. Mixed-model regressions were used to assess changes in adolescents' reports of parental encouragement from early to middle adolescence (middle school to high school) and from middle to late adolescence (high school to post-high school), and secular changes in parental encouragement among middle adolescents between the years 1999 and 2004. **RESULTS:** Longitudinally, there were significant decreases in parental encouragement to eat healthy food, be active, and diet between early and middle adolescence. Between middle and late adolescence, among males parental encouragement for all behaviors decreased,

whereas among females parental encouragement to diet increased. Few secular changes in parental encouragement were observed between 1999 and 2004. **CONCLUSION:** Given the importance of parental support for healthy eating and physical activity, efforts should be made to help parents maintain a high level of encouragement for their children's healthy behavior throughout adolescence. Parents of late adolescent females should aim to decrease the pressure on their daughters to diet during these critical developmental years.

**Croen LA, Grether JK, Yoshida CK, Odouli R, Hendrick V. Antidepressant use during pregnancy and childhood autism spectrum disorders. *Arch Gen Psychiatry* 2011 Nov; 68(11):1104-12. doi: 10.1001/archgenpsychiatry.2011.73. Epub 2011 Jul 4.**

**CONTEXT:** The prevalence of autism spectrum disorders (ASDs) has increased over recent years. Use of antidepressant medications during pregnancy also shows a secular increase in recent decades, prompting concerns that prenatal exposure may contribute to increased risk of ASD. **OBJECTIVE:** To systematically evaluate whether prenatal exposure to antidepressant medications is associated with increased risk of ASD. **DESIGN:** Population-based case-control study. Medical records were used to ascertain case children and control children and to derive prospectively recorded information on mothers' use of antidepressant medications, mental health history of mothers, and demographic and medical covariates. **SETTING:** The Kaiser Permanente Medical Care Program in Northern California. **PARTICIPANTS:** A total of 298 case children with ASD (and their mothers) and 1507 randomly selected control children (and their mothers) drawn from the membership of the Kaiser Permanente Medical Care Program in Northern California. **MAIN OUTCOME MEASURES:** ASDs. **RESULTS:** Prenatal exposure to antidepressant medications was reported for 20 case children (6.7%) and 50 control children (3.3%). In adjusted logistic regression models, we found a 2-fold increased risk of ASD associated with treatment with selective serotonin reuptake inhibitors by the mother during the year before delivery (adjusted odds ratio, 2.2 [95% confidence interval, 1.2-4.3]), with the strongest effect associated with treatment during the first trimester (adjusted odds ratio, 3.8 [95% confidence interval, 1.8-7.8]). No increase in risk was found for mothers with a history of mental health treatment in the absence of prenatal exposure to selective serotonin reuptake inhibitors. **CONCLUSION:** Although the number of children exposed prenatally to selective serotonin reuptake inhibitors in this population was low, results suggest that exposure,

especially during the first trimester, may modestly increase the risk of ASD. The potential risk associated with exposure must be balanced with the risk to the mother or fetus of untreated mental health disorders. Further studies are needed to replicate and extend these findings.

**Centers for Disease Control and Prevention. MMWR Morb Mortal Wkly Rep. 2011 Oct 7;60(39):1337-42. Nonfatal traumatic brain injuries related to sports and recreation activities among persons aged ≤19 years—United States, 2001-2009.**

Traumatic brain injuries (TBIs) from participation in sports and recreation activities have received increased public awareness, with many states and the federal government considering or implementing laws directing the response to suspected brain injury. Whereas public health programs promote the many benefits of sports and recreation activities, those benefits are tempered by the risk for injury. During 2001-2005, an estimated 207,830 emergency department (ED) visits for concussions and other TBIs related to sports and recreation activities were reported annually, with 65% of TBIs occurring among children aged 5-18 years. Compared with adults, younger persons are at increased risk for TBIs with increased severity and prolonged recovery. To assess and characterize TBIs from sports and recreation activities among children and adolescents, CDC analyzed data from the National Electronic Injury Surveillance System — All Injury Program (NEISS-AIP) for the period 2001-2009. This report summarizes the results of that analysis, which indicated that an estimated 173,285 persons aged ≤19 years were treated in Eds annually for nonfatal TBIs related to sports and recreation activities. From 2001 to 2009, the number of annual TBI-related ED visits increased significantly, from 153,375 to 248,418, with the highest rates among males aged 10-19 years. By increasing awareness of TBI risks from sports and recreation, employing proper technique and protective equipment, and quickly responding to injuries, the incidence, severity, and long-term negative health effects of TBIs among children and adolescents can be reduced. FREE FULL TEXT

**Murphy DR, Justice BD, Paskowski IC, Perle SM, Schneider MJ. The establishment of a primary spine care practitioner and its benefits to health care reform in the United States. *Chiropractic & Manual Therapies* 2011, 19:17.**

It is widely recognized that the dramatic increase in health care costs in the United States has not led to a corresponding improvement in the health care experience of patients

or the clinical outcomes of medical care. In no area of medicine is this more true than in the area of spine related disorders (SRDs). Costs of medical care for SRDs have skyrocketed in recent years. Despite this, there is no evidence of improvement in the quality of this care. In fact, disability related to SRDs is on the rise. We argue that one of the key solutions to this is for the health care system to have a group of practitioners who are trained to function as primary care practitioners for the spine. We explain the reasons we think a primary spine care practitioner would be beneficial to patients, the health care system and society, some of the obstacles that will need to be overcome in establishing a primary spine care specialty and the ways in which these obstacles can be overcome.

---

### **Adverse Effects of Vaccines: Evidence and Causality**

*Released:* August 25, 2011

*Type:* Consensus Report

*Topics:* Diseases, Public Health, Quality and Patient Safety, Children, Youth and Families, Biomedical and Health Research

*Activity:* Review of Adverse Effects of Vaccines

*Board:* Board on Population Health and Public Health Practice

Immunizations are a cornerstone of the nation's efforts to protect people from a host of infectious diseases. Though generally very rare or minor, there are side effects, or "adverse effects," associated with some vaccines. Importantly, some adverse events following a vaccine may be due to coincidence and are not caused by the vaccine. To make this distinction, researchers use evidence to determine if adverse events following vaccination are causally linked to a specific vaccine; if so, these events are referred to as adverse effects. The Health Resources and Services Administration asked the IOM to review a list of adverse events associated with

eight vaccines — varicella zoster, influenza (except 2009 H1N1), hepatitis B, HPV, MMR, hepatitis A, meningococcal, and those that contain tetanus — and evaluate the scientific evidence about the event-vaccine relationship. The IOM committee appointed to this task was not asked to assess the benefits or effectiveness of vaccines but only the risk of specific adverse events.

Using epidemiologic and mechanistic evidence, the committee developed 158 causality conclusions and assigned each relationship between a vaccine and an adverse health problem to one of four categories of causation:

- Evidence convincingly supports a causal relationship
- Evidence favors acceptance of a causal relationship
- Evidence favors rejection of a causal relationship
- Evidence is inadequate to accept or reject a causal relationship

The committee finds that evidence convincingly supports a causal relationship between some vaccines and some adverse events — such as MMR, varicella zoster, influenza, hepatitis B, meningococcal, and tetanus-containing vaccines linked to anaphylaxis. Additionally, evidence favors rejection of five vaccine-adverse event relationships, including MMR vaccine and autism and inactivated influenza vaccine and asthma episodes. However, for the majority of cases (135 vaccine-adverse event pairs), the evidence was inadequate to accept or reject a causal relationship. Overall, the committee concludes that few health problems are caused by or clearly associated with vaccines.

<http://www.iom.edu/Reports/2011/Adverse-Effects-of-Vaccines-Evidence-and-Causality.aspx>

<http://iom.edu/-/media/Files/Report%20Files/2011/Adverse-Effects-of-Vaccines-Evidence-and-Causality/Vaccine-report-brief-FINAL.pdf>



# Membership Application Form

ICA COUNCIL ON CHIROPRACTIC PEDIATRICS



## Please Print

Doctor's Name \_\_\_\_\_

Office Address \_\_\_\_\_

City \_\_\_\_\_ State/Province/Country \_\_\_\_\_

Zip/Country Code \_\_\_\_\_ Date of Birth \_\_\_\_\_

Phone Number \_\_\_\_\_ Fax Number \_\_\_\_\_

Chiropractic College of Graduation \_\_\_\_\_

Date of Graduation \_\_\_\_\_ Other Degrees/Where obtained \_\_\_\_\_

Email Address \_\_\_\_\_

National/State Chiropractic Association(s) to which you belong:

Chiropractic License # \_\_\_\_\_ State \_\_\_\_\_

Chiropractic License # \_\_\_\_\_ State \_\_\_\_\_

Chiropractic License # \_\_\_\_\_ State \_\_\_\_\_




## Dues

■ Application fee (one-time assessment) ..... \$ 15.00

■ Dues (\$180 calendar year) ..... \$ \_\_\_\_\_  
Prorated dues are \$15 a month. Start with the month you are joining and calculate through till December

Members receive FREE **Horizons** magazine and **Journal of Clinical Chiropractic Pediatrics**.



**Total** \$ \_\_\_\_\_

## Payment by:

Check (US Banks only)  MasterCard/Visa  AmericanExpress

Credit Card # \_\_\_\_\_

Expiration date \_\_\_\_\_ Security Code \_\_\_\_\_

Signature \_\_\_\_\_

## Return Application to:

**ICA Council on Chiropractic Pediatrics**

6400 Arlington Boulevard

Suite 800

Falls Church, VA 22042 USA

or fax to **(1)-703-351-7893**



... for the love of children

# Building Bridges

## Symposium on Chiropractic, Pediatrics & Research

June 22-24, 2012

The Intercontinental ■ Sydney, Australia

Experience the *Building Bridges Advantage*

- ★ 15 speakers plus research paper presenters
- ★ 20+ different tracks
- ★ Various technique workshops
- ★ Graduation of 2012 DICCPs

### Expert speakers:

- Lora Tanis, DC, DICCP
- Peter Fysh, DC, FICCP
- Sharon Vallone, DC, FICCP
- Tracy Littrell, DC, DACBR
- Joyce Miller, DC, DABCO, FCC
- Douglas DeMassa, DC, MS
- Alice Cade, BS(Chiro), DICCP
- Annica Larsdotter, MS(Chiro), DICCP
- Jennifer Barham-Floreni, BAppSc(Chiro)
- Dennis Richards, DC
- Martin Harvey, MS(Chiro)
- Eric Russell, DC, DPMCS
- Simon Floreni, BAppSc(Chiro)
- Hamish McMillan, BS(Chiro), DICCP
- Navine Haworth, DC, DICCP


### Variety of topics:

- Neuroplasticity in infants
- Adolescent problems
- Sports injuries
- Case studies in pediatric radiology
- Chiropractic adjustments and hippotherapy for kids with special needs
- Innovative physical program in martial arts to improve brain function in children with ADHD and autistic spectrum disorders
- Postpartum issues
- Pediatric research worldwide
- Principles of practice
- Pediatric case management
- Techniques for adjusting infants and pregnant women
- and more



### Congratulations!

Celebrate the graduation of the 2nd group of Diplomates in Clinical Chiropractic Pediatrics (DICCPs) in Australia/New Zealand at the Saturday night banquet.



Presented by the



**ICA Council on  
Chiropractic Pediatrics**

Co-sponsored by the

**Chiropractors' Association of Australia (National) Ltd.  
and New Zealand College of Chiropractic**

The ICA Council on Chiropractic Pediatrics is committed to educational excellence and advancing chiropractic pediatric research. Building Bridges is designed to provide you with ongoing education from experienced practitioners to help expand your clinical skills so the care you provide children and pregnant women is more effective, safe and always of a high professional standard.

To register go to:

[www.icapediatrics.com](http://www.icapediatrics.com)

For questions email:

[peditriaccouncil@chiropractic.org](mailto:peditriaccouncil@chiropractic.org)

## Register Early!!

Seating will be limited to maximize learning experience.

**HOTEL**

### The Intercontinental Hotel

117 Macquarie Street, Sydney, NSW 2000, Australia

**Group rate:** Superior City View \$255 AUD per room without breakfast; \$275 AUD with breakfast. Includes GST.

### To make reservations

Telephone: +61 2 9253 9000

Email: [reservations@interconsydney.com](mailto:reservations@interconsydney.com)

Group ID #3795722

**LIMITED ROOM BLOCK.** Will be filled on first come, first served basis.



JOURNAL OF CLINICAL CHIROPRACTIC PEDIATRICS